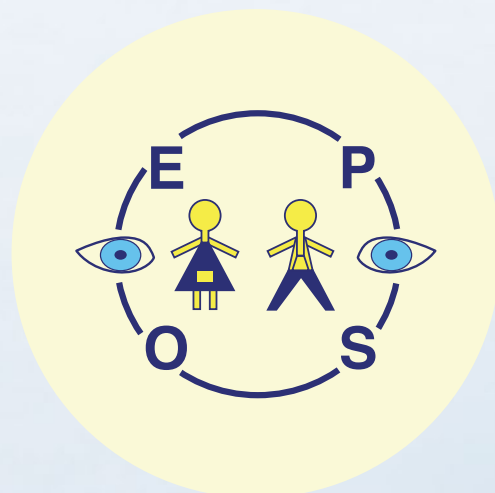


44th Annual Meeting

of the
**European Paediatric
Ophthalmological Society**

7 - 9 September 2018
Basic Medical Science Center, Semmelweis University
Budapest, Hungary

Programme & Abstract Book



owner

European Paediatric Ophthalmological Society (EPOS)

Topic and location of previous annual meetings

2001 – 2018

2018	Budapest, Hungary Imaging in paediatric ophthalmology
2017	Oxford, UK Hereditary retinal dystrophies: from genetics to gene therapy
2016	Zurich, Switzerland Paediatric Neuro-ophthalmology
2015	Saint Petersburg, Russia Innovations in Paediatric Ophthalmology
2014	Barcelona, Spain Paediatric Cataracts & Paediatric Glaucoma
2013	Leiden, The Netherlands Paediatric Ophthalmic Tumours
2012	Uppsala, Sweden Developments in Paediatric Ophthalmology
2011	Thessaloniki, Greece Visual Impairment in Childhood
2010	Bad Nauheim, Germany New Challenges in Paediatric Ophthalmology
2009	Paris, France Perinatal Ophthalmology
2008	Leuven, Belgium The Eye In Systemic Disease
2007	Portoroz, Slovenia Paediatric Electrophysiology and Psychophysics
2006	Vilamoura, Portugal Paediatric Neuro-Ophthalmology
2005	Warsaw, Poland Advances in the Surgical Treatment of Paediatric Eye Diseases
2004	Manchester, UK Developmental Genes and Eye
2003	Regensburg, Germany Gene Therapy and other Modern Therapeutic Approaches in Paediatric Degenerations
2002	Figuera Davfo, Portugal Dysmorphology of the Eye and Orbit
2001	Regensburg, Germany Trends in Paediatric Ophthalmology

As European Paediatric Ophthalmology Group (EPOG) 1973 - 2000

2000	Cambridge, UK Retinal Dystrophies
1999	Strasbourg, France Multisystem Disease and the Eye

1998	Dublin, Ireland Metabolic Disease of the Eye
1997	Cambridge, UK Neonatal Ophthalmology
1996	Valencia, Spain Neuro-Ophthalmology
1995	Cambridge, UK Dysmorphology and the Eye
1994	Regensburg, Germany Teratology and the Eye
1993	Cambridge, UK Phacomatoses
1992	Oxford, UK Retinal Receptor Dystrophies
1991	Sandjberg, Denmark Multiply handicapped and the Ophthalmologist
1990	Oxford, UK Anomalies of the Anterior Segment
1989	Bruges, Belgium Retinopathy of Prematurity
1988	Oxford, UK Genetic Diseases of the Cornea
1987	Geneva, Switzerland Neuro-Ophtalmology
1985	Oxford, UK Hearing and the Eye
1983	Amsterdam, The Netherlands Genetics and Ophthalmology
1982	Oxford, UK Ocular and Adnexal Tumours in Childhood
1981	Ghent, Belgium Genetics and Ophthalmology
1980	Geneva, Switzerland Retinal Disease in Childhood
1979	Oxford, UK Visual Development In Childhood Normal and Abnormal
1978	Freiburg, Germany Genetics and Ophthalmology
1977	Oxford, UK Nystagmus
1976	Nijmegen, The Netherlands Cataract in Childhood
1975	Copenhagen, Denmark Visually Handicapped Children The Ophthalmologist's Responsibility
1974	Oxford, UK Visual Function In Childhood
1973	Oxford, UK Retinitis Pigmentosa




Table of contents

Letter from the President	4
Letter from the Local Host	5
Committees	6
Ignác Semmelweis	7
Collection of Hungarian Values	8
General informations	10
Programme overview	16
Lecture Abstracts	22
Round Table	48
Free Paper Abstracts	50
Video Presentations	60
Rapid Fire + Poster Abstracts	64
Poster Abstracts	88
Exhibition Plan	122
Sponsors	124
Notes (inspirations, new contacts, etc.)	125

Letter from **the President**



Dear Colleagues and Friends,

It is my great pleasure to welcome you to the 44th Annual Meeting of the European Paediatric Ophthalmological Society in Budapest, Hungary.

In collaboration with the EPOS Board, our local hosts this year, Drs Erika Maka and Krisztina Knézy of the Semmelweis University, have prepared an outstanding scientific programme.

The main theme for the meeting will be "Imaging in Paediatric Ophthalmology", providing a fascinating update on recent progress in this rapidly evolving area. Further presentations will cover advances in other important fields of Paediatric Ophthalmology, including refractive error and poor vision, orbit, ocular surface disease, cataracts, glaucoma, aniridia, albinism, sickle cell disease, ROP, retinoblastoma, neurofibromatosis, optic nerve and brain hypoxia.

It is exciting to see the large number of successful contributions selected for presentation this year. In total, there will be 23 invited lectures, 13 free presentations, 40 rapid fire and 99 poster presentations.

In addition, we are introducing two new features this year: a 'roundtable' on a common problem in paediatric ophthalmology (optic disc drusen) and a new video section, presenting new surgical and clinical techniques.

The aims of our Society are to advance Paediatric Ophthalmology and to promote the development of new diagnostics and treatments for children with visual and ocular disorders.

As in previous years, Travel Awards, Best Poster and Best Presentation Prizes will be awarded at the end of the conference.

I also hope that, among the great beauty and history of Budapest, the meeting will inspire the exchange of many new ideas and innovations, and help create collaborations, fellowship and friendship in our field.

Finally, I want to acknowledge the generous support of our sponsors and encourage you to visit their exhibits during your lunch and coffee breaks.

On behalf of the EPOS Board, I would like to express our gratitude to Drs Erika Maka and Krisztina Knézy, the Tensi Conference Organisation and Semmelweis University for their hard work in hosting the 44th Annual Meeting of EPOS. I would like to sincerely thank all speakers and delegates for contributing to a fruitful and friendly meeting.

I look forward to a very productive and memorable meeting in historic Budapest.

Yours sincerely,

A handwritten signature in cursive script, reading "Darius Hildebrand".

G Darius Hildebrand
President of EPOS



Letter from **the Local Host**



Dear Colleagues,

It is a great pleasure to welcome you to the 44th Meeting of European Paediatric Ophthalmological Society. This is the first meeting of EPOS in Hungary, in our beautiful country in Central Europe, at the border of east and west. Budapest is capital city of Hungary with lot of cultural and scientific centers.

The congress venue is Basic Medical Science Center, Semmelweis University. The history of our University started almost 250 years ago in 1769, when Queen Maria Theresa added a medical faculty to the University of Nagyszombat. Not long after, the university moved first to Buda then to Pest (now Budapest). It is the oldest medical school in Hungary. Programmes are offered in four languages: Hungarian, English, German and Italian. The motto of our university is: *Servamus vitam atque servimus* ("Protecting and serving life").

This year we celebrate the 200th birthday of Ignác Semmelweis (1818-1865) who is named as the "saviour of mothers". He discovered that the incidence of puerperal fever could be prevented by the use of hand disinfection.

The main theme of this years' meeting is imaging in paediatric ophthalmology. As local host I hope you will enjoy this meeting, build your network and exchange knowledge with each other. This is the way to make a network in Europe.

I hope that you will have a lot of memorable experiences during the scientific and the social parts of this annual meeting.

Thank you very much for the opportunity to be the local host.

Welcome to Hungary!
Welcome to Budapest!
Welcome to Semmelweis University!

A handwritten signature in black ink, appearing to read 'Erika Maka'.

Erika Maka MD

*President of
Hungarian Society of Paediatric Ophthalmology
and Strabismology*



Committees of the 44TH EPOS meeting

Board of European Paediatric Ophthalmological Society

President

Göran Darius Hildebrand (*United Kingdom*)

Secretary

Eva Larsson (*Sweden*)

Treasurer

Veit Sturm (*Switzerland*)

Members

Catherina Cassiman (*Belgium*)

Anne Cees Houtman (*Netherlands*)

Matthieu P. Robert (*France*)

Sandra Valeina (*Latvia*)

Nikolas Ziakas (*Greece*)

Local Organizing Committee

Krisztina Knézy (*Hungary*)

Erika Maka (*Hungary*)

Scientific Committee

EPOS Board and the Local Organizing Committee



Ignác Semmelweis



Ignác Semmelweis was born on 1 July 1818 in Buda. He was the fifth child of his parents.

In 1829 he started his studies at the Roman Catholic University School, located in the Buda Castle area. Following his graduation from secondary school in Székesfehérvár in 1835, Semmelweis enrolled in a two-year Arts programme at the University of Pest.

He began studying law at the University of Vienna in 1837, but by the following year he had switched to medicine. He studied at the University of Pest's Medical Faculty between 1839-1841. He was awarded his doctorate degree in medicine with his botanically-themed dissertation, entitled *Tractatus de Vita Plantarum* in Vienna in 1844. That same year, he earned Master Obstetrician certificate, and Master Surgeon certificate in 1845.



In March 1847, he travelled to Venice on vacation, during which time his good friend Jakob Kolletschka, a professor of forensic medicine, died in Vienna. Following his return, Semmelweis examined Kolletschka's autopsy report, and discovered that the disease which had caused his death and that, which was known as childbed (or, puerperal) fever, were one and the same. Semmelweis came to the realisation that it was the doctors themselves who caused childbed fever by not disinfecting their hands between performing autopsies and examining expectant women in the maternity ward. It became clear to him that this was the explanation behind the fact that childbed fever was a much rarer phenomenon among pregnant women treated exclusively by midwives and midwives-in training than among those also treated by doctors and medical students.

After trying several chemicals, Semmelweis finally settled on chlorinated lime in the spring of 1847 as his disinfectant of choice. He ordered all doctors, medical students, and nurses to wash their hands with the chlorinated lime solution before entering the maternity wards and, in October, made hand washing between examining patients mandatory, as well. His views were very unpopular and his colleagues did not take the results seriously.

He was appointed Professor of Theoretical and Practical Obstetrics at the University of Pest in 1855. Semmelweis spent six years as the head of Rókus Hospital's maternity ward, during which time the mortality rate from childbed fever at the hospital dropped.

Meanwhile, the office of the director of the obstetrics department in Vienna became vacant in 1855, but Semmelweis was not nominated for the position. Two years later, the University of Zurich offered him a position as professor, but he turned down the invitation.

With the encouragement of his friends, Semmelweis first published his discovery and results about aseptic procedure in 1858, in *Orvosi Hetilap* [Medical Weekly]. In 1860, Semmelweis published a book in German, entitled *Die Aetiologie, der Begriff und die Prophylaxis des Kindbettfiebers* [The Etiology, Concept and Prophylaxis of Childbed Fever]. This was followed by his first and second open letters written to colleagues, also published in German in 1861 and 1862, respectively. Due to his new ideas and his passionate tone his views were rejected and attacked by the majority of Hungarian doctors and doctors from abroad as well.

Years before his death Semmelweis's behaviour started to become unusual. Because of the constant attacks and the serious self-accusation after his discovery about the childbed fever he started to have serious problems with his nervous system, which ended up in a mental illness in July 1865. Semmelweis's wife turned to Professor Hebra for help, who was their friend in Vienna. With his intervention Semmelweis was admitted to the Viennese Mental Hospital in Döbling on July 31. Semmelweis passed away on August 13.

The circumstances about his death have been the subject of scientific debates for decades. According to the autopsy report and a pathological and radiological examination performed on Semmelweis's bones in 1963-1964, the cause of death was sepsis resulting from a subacute osteomyelitis on his right hand. He died of the same disease he himself had described.

Ignác Semmelweis is notable not only as an obstetrician, but for his work as a surgeon as well. Indeed, he performed the first ovarian surgery and the second Caesarean section in Hungary. His wife brought his ashes back to Budapest from Vienna in 1891, laying him to rest in the family crypt. Ignác Semmelweis found his final resting place in 1965, when his ashes were moved to the courtyard of his birth house, which currently houses the Semmelweis Museum of Medical History.

Semmelweis University adopted the name of its former professor, Ignác Semmelweis in 1969.

A collection of Ignác Semmelweis's printed materials on his discoveries related to childbed fever was inscribed in UNESCO's Memory of the World Register in 2013.



Collection of Hungarian Values

Collection of Hungarikums

The Parliament adopted the Act XXX of 2012 on Hungarian national values and Hungarikums with a consensus between the five major parties with the aim of establishing appropriate legal framework for the identification, collection and documentation of national values important for the Hungarian people and by this providing an opportunity for making them available to the widest possible audience and for their safeguarding and protection. The act wishes to establish a supportive legal framework for the “Hungarikum movement”, an extensive civil initiative already in place.

According to the legal definition Hungarikum refers to a collective term denoting a value worthy of emphasis that represents the highest quality of Hungarian product with its characteristically Hungarian attributes, uniqueness, special nature and quality.

Agriculture and Food Industry

1. Pálinka
2. Grape marc pálinka
3. Csabai sausage or Csabai thick sausage
4. Tokaji aszú produced in the Tokaj wine region of Hungary
5. Food products from fattened goose
6. Gyulai sausage or Gyulai double sausage
7. Soda-water
8. Ground paprika from Kalocsa
9. PICK wintersalami
10. Black locust (*Robinia pseudoacacia*)
11. Hungarian acacia honey
12. HERZ classic wintersalami
13. Red onions from Makó
14. Ground paprika from Szeged
15. Hungarian grey cattle
16. UNICUM herbal liqueur
17. Debrecen double sausage
18. Spritzer
19. Alföld chamomile
20. Chimney cake
21. Piros Arany (Red Gold) and Erős Pista
22. TÖRLEY Sparkling Wine
23. Egri Bikavér
24. Hungarian shepherd and hound dogs

Health and Lifestyle

25. Béres drops and Béres drops extra
26. ILCSI Organic Skin Care Products
27. Hungarian District Nursing Service as an internationally unique, traditional healthcare system
28. Lake Hévíz and the traditional therapy in Hévíz
29. Life-work of János Kabay, founder of the Alkaloida pharmaceutical factory

Industrial and technological solutions

30. KÜRT Data Recovery
31. Zsolnay porcelain and ceramics
32. Life-work of János Neumann in the area of information technology and computers

Cultural Heritage

33. The folk dance house method as the Hungarian model of perpetuation of cultural heritage
34. „Mohácsi Busó járás” a masked end-of-winter tradition
35. Falconry as a living human heritage
36. Matyó folk art – The embroidery culture of a traditional community



- 37. Budapest, including the banks of the Danube, the Buda castle quarter and Andrásy avenue
- 38. Old village of Hollókő and its surroundings
- 39. Millenary Benedictine Abbey of Pannonhalma and its natural environment
- 40. Hortobágy National Park – the Puszta
- 41. Early Christian necropolis of Pécs (Sopianae)
- 42. Fertő / Neusiedlersee cultural landscape
- 43. Tokaj historic wine region cultural landscape
- 44. Herend porcelain
- 45. Hungarian operetta
- 46. The Kassai method of horseback archery
- 47. Halas lace
- 48. Kalocsa folk art – drawing, embroidery and wall painting
- 49. Budapest Gypsy Symphony Orchestra – The worldrenowned artistic and tradition preserving practice of the orchestra
- 50. Count István Széchenyi’s intellectual legacy
- 51. Traditional Hungarian folk song
- 52. Zsolnay Cultural Quarter
- 53. Tárogató
- 54. The Vizsoly Bible
- 55. The Hungarian bow of the 9th-11th century.
- 56. Hungarian dulcimer

- 57. Kodály concept
- 58. The Hungarian farmstead
- 59. Hungarian hussar
- 60. The Order of Saint Paul the First Hermit
- 61. Hollóháza Porcelain

Sport

- 62. The worldknown and renowned life-work of Ferenc Puskás

Natural environments

- 63. Caves of Aggtelek karst and Slovak karst
- 64. Hive-stones and the stone culture of Bükkalja

Tourism and catering

- 65. Karcag mutton stew
- 66. Gundel heritage – gastronomic and catering trade heritage of Károly Gundel and the Gundel Restaurant
- 67. Fish soup from Baja
- 68. Fisherman’s soup from the region of Tisza
- 69. Gulash soup

Built Environment

- 70. Built environment of Torockó

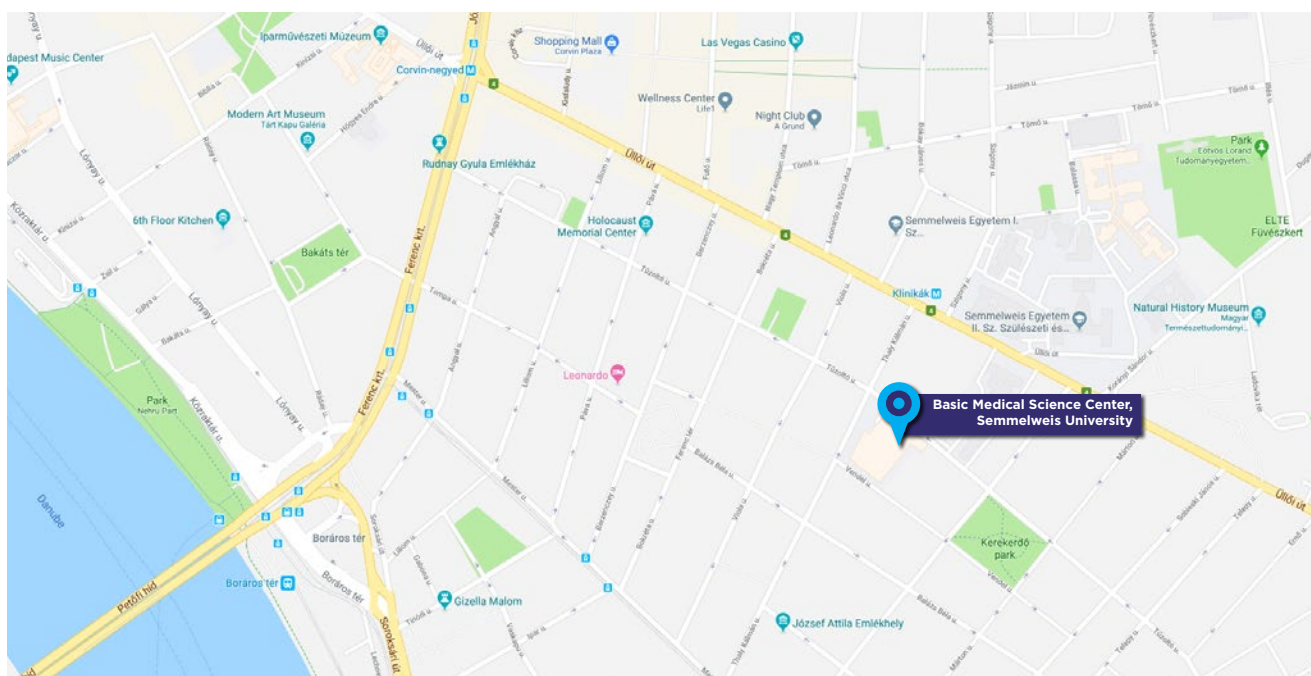


General informations

Venue

Basic Medical Science Center,
Semmelweis University, Budapest, Hungary
H-1094 Budapest, Tűzoltó utca 37-47.
www.semmelweis.hu/eok/en

Szent-Györgyi lecture hall: Lectures, Free Papers, Video presentations and Rapid fires
1st floor Gallery: Posters
Ground floor Foyer: Exhibition



Organizing Secretariat

TENSI LTD.

Komjádi Béla u. 1.
1023 Budapest, Hungary
Tel.: +36-1-345 1567
E-mail: congress@tensi.hu
Web: <https://tensi-congress.hu>



Congress Secretariat and Registration desk is located on the right side at the main entrance of the Congress venue. The registration desk - where advanced and on-site registrants may pick up their meeting material is operating in the following hours:

Friday	7 th September 2018	18:00 pm - 20:00 pm
Saturday	8 th September 2018	07:00 am - 18:00 pm
Sunday	9 th September 2018	07:30 am - 16:00 pm

For any assistance please do not hesitate to contact us.



Currency and money

The Hungarian currency is the forint (Ft and HUF). If you want to exchange your currency to forint, always do so at an official exchange office. Never exchange money on the streets with random strangers, since this is prohibited by law. There are ATMs on almost every corner in Budapest, and you can find at least one ATM in every city countrywide. Money withdrawal from ATMs is in forint. All major credit and debit cards (MasterCard, Visa, etc.) are accepted. If you want to use a card and you have doubts about whether it is accepted, please look for the usual window stickers. Note: card acceptance is not obligatory, so always carry some cash in forints. Cash payments that don't end in 5 or 0 will be rounded to the closest 5 or 0, e.g. for HUF 152 you pay HUF 150 and for HUF 158 you pay HUF 160. All prices in shops are gross prices including VAT.

Tipping

There's no general rule, but 10% of the final price is usually expected in restaurants, pubs, cafés and taxis. There are restaurants where the service fee is already included in the price, so check the bill before tipping. Another way is rounding up: you can tip by saying how much you want to pay (e.g. HUF 6,000 instead of HUF 5,700). Be careful about saying "Thank you!" when paying. If you say it while handing over the money, this is informally taken to mean that you don't expect any change to be given back.

Electricity

The voltage in Hungary is AC 230 V / 50 Hz. Electrical plugs are „Type F” (for European standard 2 pin sockets). Visitors from abroad will need an adaptor for appliances that have been brought from home, such as laptops, hairdryers, and phone chargers. If needed, travel adaptors are available in stores that sell electrical appliances or in any mall.

Emergency hotline

112. Once you have dialled the number, the dispatcher connects you to the corresponding service (ambulance, police, fire dept.). Calls are free from any public or private phones, but they should only be made in real emergencies. In case of a medical emergency, the ambulance will take patients to the nearest available hospital (“kórház” in Hungarian). If you would like to go to a hospital by yourself, there are a few options, but keep in mind that not all hospitals have doctors on call to take patients that just drop in. Unless it's an emergency, hospital treatment requires a doctor's referral. Some emergency clinics (“éjszakai orvosi ügyelet”) are open at night and on weekends when general-practice clinics are closed. There are a number of private clinics catering to expats and foreign tourists, with doctors that speak many languages. These can be more expensive, but if you have travel insurance your costs could be covered. Expat or tourist medical clinics may have direct billing relationships with some insurers.

For residents of the European Union (plus Iceland, Norway, Liechtenstein, and Switzerland) “basic healthcare” is free. Have a European Health Insurance Card (EHIC) and passport or ID ready to show to medical staff. You must get your EHIC before arriving in Hungary (or be able to get one and present it within 15 days of treatment), otherwise medical care must be paid for. This “basic care” doesn't cover non-emergencies or emergency repatriation. The EHIC doesn't cover pre-existing conditions or “medical tourism” either, but chronic conditions are covered. Subsidies on medicines vary and EU residents (with ID) might be eligible; this will be calculated as you pay at pharmacies.

Only emergency first-aid assistance is free – foreign tourists must pay for all other types of medical



General informations

care and medicines. Costs will vary greatly between doctors working at publicly run clinics and those working privately.

Pharmacies („gyógyszertár” in Hungarian) are easily recognisable by their illuminated green cross signs and distinctive snake around the bowl of Hygieia signs. Pharmacies in Budapest are usually well stocked, and pharmacists may be able to suggest medication for certain complaints. A notice on the door of pharmacies indicates the address of the closest 24-hour pharmacy. You can also find several pharmacies where no prescription is required – they sell products such as painkillers, bandages – at petrol stations or in selected department stores (e.g. Drogerie Markt, Rossmann or Müller).

Internet

Most hotels/hostels include Internet facilities as part of their service (it's usual, but not always free of charge). Cafés, pubs, and restaurants usually offer free Wi-Fi Internet access. There's a free Wi-Fi service on Intercity trains and selected bus lines. Mobile network coverage is excellent in Hungary - LTE networks are even available in the countryside.

Opening hours: Most shops are open from 7 a.m. to 6 p.m. on weekdays, while malls are generally open every day from 9 a.m. to 10 p.m. Outside Budapest and other main cities, many businesses and stores still close on Sundays, but in the larger cities you can expect most shops to be open.

Taxes

In most cases standard Value Added Tax (VAT) in 2018 is payable at a rate of 27%. There is a reduced rate of 18%, relating to hotels and basic food and a 5% rate that relates mainly to products and services such as books and medicines.

Taxi

There are yellow cabs in Budapest's streets which belong to the official taxi companies. You can use it within the city and to the airport as well. You can pay in cash (Hungarian Forint) or by credit card. All cabs have a price table and you can check the amount in a screen.

Phone number: +36 1 777 7777

Telephone

The international code for Hungary is 36; the area code for Budapest is 1.

Time zone

Hungary is in the Central European Time Zone (GMT+1).

Weather

Hungary has a mild continental climate with four distinct seasons. Summers are hot with low overall humidity levels but frequent rain showers, while the winter is cold and snowy. Average high temperature in the summer is 23 to 28°C and average low temperature in the winter is -3 to -7 °C.

Weights and measures

Hungary uses the Metric system, which has been compulsory since 1876.




Schedule of the meeting

7th September 2018 - Friday

- 18:00 - 20:00 Registration for pre-registration participants
 Onsite registration
 Poster mounting
- 20:00 - 21:30 Opening and Welcome reception with buffet for all participants:
 Venue: Basic Medical Science Center, Semmelweis University, Budapest, Hungary

8th September 2018 - Saturday

- 7:00 - 18:00 Registration for pre-registration participants
 Onsite registration
- 8:00 - 17:30 Scientific programme
- 17:30 - 18:30 EPOS General Assembly for EPOS members
- 19:00 - Gala Dinner for all participants
 Venue: Cruise on the River Danube
 Meeting point: in front of the Congress venue from where hostesses will coordinate
 the transfer. Please look for them in red T-shirt with Gala dinner sign.



9th September 2018 - Sunday

- 7:30 - 16:00 Registration for pre-registration participants
 Onsite registration
- 8:00 - 16:00 Scientific programme
- 16:00 - 17:00 Closing remarks, Award ceremony



General informations

Accreditation and Certificate of attendance

The 44th annual meeting of the European Paediatric Ophthalmological Society (Budapest, Hungary, 07/09/2018-09/09/2018) has been accredited by the European Accreditation Council for Continuing Medical Education (EACCME®) for a maximum of 13 European CME credits (ECMEC®s)

Badge

Participants will receive a badge upon arrival at the registration desk. Since your personal badge is your entrance ticket to the meeting, please make sure that you wear your badge at all times during all activities.

Cloakroom

We ask you not to take coats or large bags into the lecture hall. Please use the free cloakroom on the ground floor as it is noted.

Language

The official language of the meeting is English

Non-smoking policy

Smoking is prohibited inside of the building.

Photography

Please note that an official photographer will be present during the meeting. For your kind information, the photos will be protected by EPOS and will be available on the EPOS congress websites after the congress.

Wi-Fi

Network: Konferencia

Password: Budapest2017



Instruction for presentations

This year we will have 23 Lectures, 13 Free Papers, 3 Video Presentations, 40 Rapid Fire + Poster Presentations, 59 Posters, 1 Round Table.

Free paper and Video Presentation

The Free Paper and Video Presentation consist on 5 minutes presentation and 2 minutes discussion. You are kindly requested not to exceed the assigned time. The moderators of each session will be strict with the accomplishment of the time.

Presentations must be done only in PowerPoint. You will need to bring your data file in USB memory to the venue. It will not possible to use a personal laptop. If your presentation includes sound or movie(s), do not forget to bring your video in a separate file.

You are requested to come to the Speakers' Pre-view Room to upload your presentation at least two hours before.

Rapid Fire

The Rapid Fire consists on 3-4 slides, 2 minutes presentation and 1 minute discussion.

Given the short time assigned, and in order to save time between presentations, you are requested to take your position during the last minute of your predecessor.

Presentations must be done only in PowerPoint. You will need to bring your data file in USB memory to the venue. It will not possible to use a personal laptop. If your presentation includes sound or movie(s), do not forget to bring your video in a separate file.

You are requested to come to the Speakers' Pre-view Room to upload your presentation at least two hours before.

Poster

The Posters have to be presented printed.

Poster format: Portrait A0 (84.1 cm x 118.9 cm); the poster must not exceed these dimensions.

Posters will be displayed throughout the Meeting. We would ask the authors to mount the posters on the panel by Saturday 8:00 AM. It is possible to mount the posters already on Friday between 6:00 - 8:00 PM. We would kindly ask not to dismount the posters before Sunday 4:00 PM.

The Poster sessions are scheduled as follow:

Poster session 1: P 1 to P 10 - 8th September 10:30 - 11:00

Poster session 2: P 11 to P 20 - 8th September 13:30 - 14:00

Poster session 3: P 21 to P 30 - 8th September 15:30 - 16:00

Poster session 4: P 31 to P 40 - 9th September 9:30 - 10:00

Poster session 5: P 41 to P 50 - 9th September 12:30 - 13:00

Poster session 6: P 51 to P 59 - 9th September 14:30 - 15:00

During the session, the author must be at the panel, to answer questions of the attendants.



Programme overview

7th September 2018 (Friday)

Registration	Social events	Scientific Program
18:00-20:00		
	20:00 Welcome and Social Reception	

8th September 2018 (Saturday)

Registration	Social events	Scientific Program
7:00-18:00		8:00 Welcome and Opening Remarks
		President of EPOS President of Hungarian Ophthalmological Society President of Hungarian Society of Paediatric Ophthalmology and Strabismology Director of Dept.of Ophthalmology, Semmelweis University
		8:30 - 10:30 Scientific Program
		Session 1 Brain Hypoxia Optic nerve
		L1 Hypoxia induced encephalopathy - neonatology
		Miklos SZABO (Hungary)
		L2 The role of MRI in the diagnosis of neonatal asphyxia
		Gabor RUDAS (Hungary)
		Free Paper and Rapid Fire Presentations
		L3 Retinal Oximetry in a pediatric population
		Nicoline SCHALIJ-DELFO (Netherlands)
		L4 Normal and abnormal foveal and optic nerve development in infancy
		Irene GOTLOB (UK)
		Free Paper and Rapid Fire Presentations
		10:30 - 11:00 Coffee Break and Poster Exhibition
		11:00 - 13:00 Scientific Program
		Session 2 Ophthalmic imaging Myopia Cataract
		L5 Basic principles of state-of-the art ophthalmic imaging technology
		Kristina IRSCH (USA)
		L6 Efficacy and safety of interventions to control myopia progression in children: An overview of systematic reviews and meta-analyses
		Nikolas ZIAKAS (Greece)
		Free Paper and Rapid Fire Presentations
		L7 Paediatric IOL implants - a growing choice
		Göran Darius HILDEBRAND (UK)
		L8 The retrolenticular space revisited using intraoperative OCT
		Marie-José TASSIGNON (Belgium)
		Free Paper and Rapid Fire Presentations
		13:00 -14:00 Lunch Break and Poster Exhibition
		14:00 - 15:30 Scientific Program
		Session 3 Glaucoma Aniridia Albinism
		L9 Imaging of trabecular meshwork
		Annegret DAHLMANN-NOOR (UK)
		L10 Surgical Aspects in Paediatric Glaucoma
		John BROOKS (UK)
		Free Paper and Rapid Fire Presentations
		L11 Imaging of the Ocular Surface in Congenital Aniridia
		Neil LAGALI (Sweden)
		Free Paper and Rapid Fire Presentations
		15:30 - 16:00 Coffee Break and Poster Exhibition
		16:00 - 17:30 Scientific Program
		Session 4 Sickle cell disease Retinoblastoma
		L12 Retinal Imaging in Sickle Cell Disease
		Matthieu P ROBERT (France)
		Free Paper and Rapid Fire Presentations
		L13 Imaging in Retinoblastoma Management
		Francis MUNIER (Switzerland)
		L14 Intra-Arterial Chemotherapy in Retinoblastoma
		Francesco PUCINELLI (Switzerland)
		Free Paper and Rapid Fire Presentations
		17:30 - 18:30 EPOS General Assembly
		20:00 - Conference Dinner

Programme overview



9th September 2018 (Sunday)

Registration	Social events	Scientific Program				
7:30 - 16:00		8:00 - 9:00 Scientific Program	Session 5 Orbit	L15 Orbital distraction for faciocraniosynostosis	Eric ARNAUD (France)	
				L16 Imaging in paediatric orbital tumours	Pim de GRAAF (Netherlands)	
				Free Paper and Rapid Fire Presentations		
		9:00 - 9:30 Scientific Program	Session 6 Optic disc drusen	Round table about optic disc drusen	Göran Darius HILDEBRAND (UK) Irene GOTLOB (UK) Lasse MALMQVIST (Denmark) Cameron PARSA (France) Guenther RUDOLPH (Germany)	
				Free Paper and Rapid Fire Presentations		
				9:30 - 10:00 Coffee Break and Poster Exhibition		
		10:00 - 12:00 Scientific Program	Session 7 ROP	L17 Telemedicine in ROP	Graham QUINN (USA)	
				Free Paper and Rapid Fire Presentations		
				L18 Imaging of the ocular vasculature in prematures	Birgit LORENZ (Germany)	
				Free Paper and Rapid Fire Presentations		
				L19 Characteristics of central macular region in preterm babies	Anna MOLNAR (Sweden)	
				Free Paper and Rapid Fire Presentations		
	12:00 - 13:00 Lunch Break and Poster Exhibition					
		13:00 - 14:30 Scientific Program	Session 8 Cystinosis Neurofibromatosis Retinal imaging	L20 Nephropathic Cystinosis: Looking beyond the Crystals	Susmito BISWAS (UK)	
				Free Paper and Rapid Fire Presentations		
				L21 Imaging in NF1	Catherine CASSIMAN (Belgium)	
				Free Paper and Rapid Fire Presentations		
				L22 Imaging in paediatric retina	CK Patel (UK)	
				Free Paper and Rapid Fire Presentations		
	14:30 - 15:00 Coffee Break					
		15:00 - 16:00 Scientific Program	Session 9 Retinal diseases	Free Paper and Rapid Fire Presentations		
				L23 Acute Stage 4 Retinopathy of Prematurity: UK National Outcomes of Combined Endoscopic and Conventional Vitrectomy	Chien WONG (UK)	
Video Presentations						
16:00 - 17:00						
Awards. Presentation for next year. Closing Remarks.						



Scientific Program

8th September 2018 (Saturday)

8:30 - 10:30	Session 1	Brain Hypoxia Optic nerve		Chairpersons:	Krisztina Knezy (Hungary) Veit Sturm (Switzerland) Cameron Parsa (USA)	
			L 1	Miklos Szabo (Hungary)	Hypoxia induced encephalopathy - neonatology	8:30 - 8:50
			L 2	Gabor Rudas (Hungary)	The role of MRI in the diagnosis of neonatal asphyxia	8:50 - 9:10
			FP 1	Jose TORRES-PENA (Spain)	Idiopathic intracranial hypertension in pediatric population	9:10 - 9:18
			FP 2	Zhanhan Tu (United Kingdom)	Optical Coherence Tomography Provides Insights into the Pathology of Cerebral Malaria	9:18 - 9:26
			RF 1	Amit Chhabra (United Kingdom)	Low Incidence of Cerebral Venous Thrombosis in a 'Real World' Population of Paediatric Intracranial Tumours	9:26 - 9:29
			L 3	Nicoline Schalijs-Delfos (Netherlands)	Retinal Oximetry in a pediatric population	9:30 - 9:50
			L 4	Irene Gotlob (United Kingdom)	Normal and abnormal foveal and optic nerve development in infancy	9:50 - 10:10
			RF 2	Diogo Hipólito Fernandes (Portugal)	Large cup/disc ratio in Pediatric Age - SD-OCT and OCT-A evaluation	10:10 - 10:13
			RF 3	Diem Trang Nguyen (France)	The optic nerve in morning glory disk anomaly. An MRI study	10:13 - 10:16
			RF 4	Claudia Priglinger (Germany)	A retrospective analysis of Leber's Hereditary Optic Neuropathy (LHON) in childhood and treatment with idebenone	10:16 - 10:19
			RF 5	Zsuzsa Erdei (Hungary)	Clinical experience with idebenone treatment of adolescents with Leber's Hereditary Optic Neuropathy - 3 case reports	10:19 - 10:22
10:30 - 11:00	Poster Session 1	Poster 1 - 10				
11:00 - 13:00	Session 2	Ophthalmic imaging Refractive errors Ocular surface Cataract		Chairpersons:	Göran Darius Hildebrand (United Kingdom) Ildiko Süveges (Hungary) Marie-José Tassignon (Belgium)	
			L 5	Kristina Irsch (USA)	Basic principles of state-of-the art ophthalmic imaging technology	11:00 - 11:20
			L 6	Nikolas G. Ziakas (Greece)	Efficacy and safety of interventions to control myopia progression in children: An overview of systematic reviews and meta-analyses	11:20 - 11:40
			FP 3	Annegret Dahlmann-Noor (United Kingdom)	Myopia increase in London - progression rate similar in children of different ethnic backgrounds and faster in girls	11:40 - 11:48
			RF 6	Alina Bakunowicz-Lazarczyk (Poland)	Selected antioxidant microelements serum concentration in myopic children and adolescents	11:48 - 11:51
			FP 4	Huda Al-Hayouti (United Kingdom)	Meibography and corneal volume optical coherence tomography to quantify damage to ocular structures in children with blepharokeratoconjunctivitis	11: 51 - 11:59
			RF 7	Huda Al-Hayouti (United Kingdom)	Automated image quantification of conjunctival hyperaemia to measure activity of blepharokeratoconjunctivitis in children	11: 59 - 12:02
			L 7	Göran Darius Hildebrand (United Kingdom)	Paediatric IOL implants - a growing choice	12:02 - 12:22
			L 8	Marie-José Tassignon (Belgium)	The retrolenticular space revisited using intraoperative OCT	12:22 - 12:42
			FP 5	Annegret Dahlmann-Noor (United Kingdom)	Childhood lensectomy: associated with an arrest in foveal development	12:42 - 12:50
			RF 8	Daniel Jackson (United Kingdom)	Outcomes of paediatric cataract surgery following Proton Beam Radiotherapy (PBRT) for Orbital Rhabdomyosarcoma (RMS)	12:50 - 12:53
			RF9	João Leandro (Portugal)	The Adequacy of the Fogging Test in the Detection of Clinically Significant Hyperopia in School-Aged Children	12:53 - 12:56
13:30 - 14:00	Poster Session 2	Poster 11 - 20				

Scientific Program



8th September 2018 (Saturday)

14:00 - 15:30	Session 3	Glaucoma Aniridia Albinism Poor vision Ocular surface		Chairpersons:	Nikolas G. Ziakas (Greece) John Brooks (United Kingdom) Maria Bausz (Hungary)	
			L 9	Annegret Dahlmann-Noor (United Kingdom)	Imaging of trabecular meshwork	14:00 - 14:20
			L 10	John Brooks (United Kingdom)	Surgical aspects in paediatric glaucoma	14:20 - 14:40
			FP 6	Ian Christopher Lloyd (United Kingdom)	Glaucoma following surgery for congenital cataract	14:40 - 14:48
			L 11	Neil Lagali (Sweden)	Imaging of the Ocular Surface in Congenital Aniridia	14:48 - 15:08
			RF 10	Siobhan Ludden (United Kingdom)	Anterior segment OCT to evaluate the effectiveness of cycloplegia in children	15:08 - 15:11
			RF 11	Shalhevet. Goldfeather Ben Zaken (Israel)	Foveal hypoplasia as a cause for unexplained poor visual acuity	15:11 - 15:14
			RF 12	Jorge Meira (Portugal)	Morphological evaluation of the macular retina in amblyopia	15:14 - 15:17
			RF 13	John E A Somner (United Kingdom)	Hermansky Pudlack Syndrome - why it takes more than a circumcision to make the diagnosis	15:17 - 15:20
			RF 14	Alenka Lavrič Groznik (Slovenia)	Clinical and anterior segment OCT features of conjunctival nevi in children	15:20 - 15:23
15:30 - 16:00	Poster Session 3	Poster 21 - 30				
16:00 - 17:30	Session 4	Sickle cell disease Retino-blastoma Pseudoretino-blastoma		Chairpersons:	Matthieu P. Robert (France) Guenther Rudolph (Germany) Bela Csakany (Hungary)	
			L 12	Matthieu P. Robert (France)	Retinal Imaging in Sickle Cell Disease	16:00 -16:20
			RF 15	Gilles Martin (France)	Paramacular retinal atrophy and cerebral vasculopathy in homozygous sickle cell disease	16:20 - 16:23
			L 13	Francis Munier (Switzerland)	Imaging in Retinoblastoma Management	16:23 -16:43
			L 14	Francesco Pucinelli (Switzerland)	Intra-Arterial Chemotherapy in Retinoblastoma	16:43 - 17:03
			FP 7	Christina Stathopoulos (Switzerland)	Simple, double and triple cloud in retinoblastoma: role of dynamic B-scan ultrasonography	17:03 - 17:11
			RF 40	Marie-Claire Gaillard (Switzerland)	Invisible Retinoblastoma: the role of OCT	17:11 - 17:14
			RF 16	Damien Yeo (United Kingdom)	Diagnostic difficulties in retinoblastoma: an analysis of pseudoretinoblastomas in a tertiary referral centre in the UK.	17:14 - 17:17
			RF 17	Guenther Rudolph (Germany)	Familial exudative vitreo-retinopathy - FEVR. A diagnostic and treatment challenge	17:17 - 17:20

■ Lecture Abstracts
 ■ Free Paper Abstracts
 ■ Rapid Fire Abstracts
 ■ Poster Session



Scientific Program

9th September 2018 (Sunday)

8:00 - 9:00	Session 5	Orbit		Chairpersons:	Pim de Graaf (Netherlands) Olga Lukats (Hungary) Sandra Valeina (Latvia)	
			L 15	Eric Arnaud (France)	Orbital distraction for faciocraniosynostosis	8:00 - 8:20
			L 16	Pim de Graaf (Netherlands)	Imaging in paediatric orbital tumours	8:20 - 8:40
			FP 8	Amit Chhabra (United Kingdom)	Apraclonidine in diagnosis of Partial Horner Syndrome in children.	8:40 - 8:48
			RF 18	Evangelia Ntoula (Sweden)	Ophthalmological findings in infants with non-syndromic craniosynostosis : a preliminary report	8:48 - 8:51
			RF 19	Sally Painter (United Kingdom)	Unilateral ptosis is rarely amblyogenic	8:51 - 8:54
			RF 20	Maria Samouilidou (Greece)	Congenital Nasolacrimal Duct Obstruction preferred practice patterns among EPOS members	8:54 - 8:57
			RF 21	Mervyn Thomas (United Kingdom)	Optic Nerve Head Abnormalities Associated with Congenital Fibrosis of Extraocular Muscles	8:57 - 9:00
9:00 - 9:30	Session 6	Optic Disc Drusen		Moderator: Göran Darius Hildebrand (United Kingdom)	Panelists: Irene Gotlob (United Kingdom) Lasse Malmqvist (Denmark) Cameron Parsa (USA) Guenther Rudolph (Germany)	
		Round Table				
			RF 22	Filipa Teixeira (Portugal)	Optic Disc Drusen in Children: Morphologic features using enhanced depth imaging optical coherence tomography.	
9:30 - 10:00	Poster Session 4	Poster 31 - 40				
10:00 - 12:00	Session 7	ROP		Chairpersons:	Eva Larsson (Sweden) Birgit Lorenz (Germany) Erika Maka (Hungary)	
			L 17	Graham Quinn (USA)	Telemedicine in ROP	10:00 - 10:20
			RF 23	Aylin Taner (Switzerland)	Improved survival lead to higher ROP incidence in extremely preterm infants	10:20 - 10:23
			RF 24	Stella Moutzouri (Greece)	Retinopathy of prematurity: frequency and associated risk factors in a large Greek cohort.	10:23 - 10:26
			RF 25	Anna Chmielarz-Czarnocińska (Poland)	The role of platelet count in the pathogenesis of retinopathy of prematurity.	10:26 - 10:29
			RF 26	Dimitrios Kardaras (Greece)	The association between retinopathy of prematurity and ocular growth	10:29 - 10:32
			RF 27	Anna Chmielarz-Czarnocińska (Poland)	Results of treatment of retinopathy of prematurity in Poland, a single center analysis.	10:32 - 10:35
			FP 9	Kasia Trzcionkowska (Netherlands)	Treatment of Retinopathy of Prematurity in the Netherlands between 2010-2016	10:35 - 10:43
			L 18	Birgit Lorenz (Germany)	Imaging of the ocular vasculature in prematures	10:43 - 11:03
			RF 28	Irina Trifanenkova (Russia)	Informativeness of optical coherence tomography-angiography in children with active stages of retinopathy of prematurity	11:03 - 11:06
			L 19	Anna Molnar (Sweden)	Characteristics of central macular region in preterm babies	11:06 - 11:26
			FP 10	Kerstin Hellgren (Sweden)	Visual cognitive problems captured with a structured history inventory in extremely preterm born children aged 6.5 years	11:26 - 11:34
			FP 11	Eva Larsson (Sweden)	Visual function is reduced in formerly prematurely born young adults - a population-based study.	11:34 - 11:42
			RF 29	Yaroslava Wenner (Germany)	Comparison of the optic nerve head parameters and RNFL in premature and full term children with OCT	11:42 - 11:45
			RF 30	Ana Ortueta-Olartecoechea (Spain)	Retinal ganglion cells complex in preterm children at childhood	11:45 - 11:48
			RF 31	Ana Ortueta-Olartecoechea (Spain)	Retinal ganglion cells complex and neonatal determinants: an optical coherence tomography study in very preterm children at school-age	11:48 - 11:51

Scientific Program

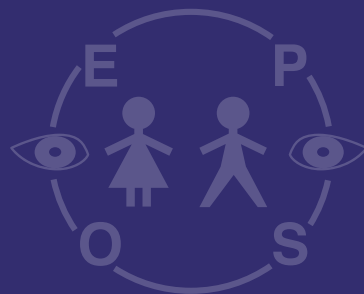


9th September 2018 (Sunday)

12:30 - 13:00	Poster Session 5	Poster 41 - 50				
13:00 - 14:30	Session 8	Cystinosis Neuro-fibromatosis Retinal imaging		Chairpersons:	Catherine Cassiman (Belgium) Kristina Irsch (USA) Zoltán Zsolt Nagy (Hungary)	
			L 20	Susmito Biswas (United Kingdom)	Nephropathic Cystinosis: Looking beyond the Crystals	13:00 - 13:20
			RF 32	Anita Csorba (Hungary)	Using in vivo confocal microscopy and anterior segment optical tomography in nephropathic cystinosis	13:20 - 13:23
			RF 33	Hajnalka Horvath (Hungary)	Comparison of quantitative measurement of foveal avascular zone and macular vessel density in eyes of children with chronic kidney disease and healthy controls	13:23 - 13:26
			L 21	Catherine Cassiman (Belgium)	Imaging in NF1	13:26 - 13:46
			FP 12	Urszula Kulik (Sweden)	Optical coherence tomography in the evaluation of children with neurofibromatosis type 1.	13:46 - 13:54
			FP 13	Cameron Parsa (USA)	Brushfield spots and Wölfflin nodules unveiled in dark irides using near-infrared light	13:54 - 14:02
			L 22	CK Patel (United Kingdom)	Imaging in paediatric retina	14:02 - 14:22
			RF 34	Eva Roomets (Estonia)	Wide-Field Autofluorescence Imaging for Follow-up of LCHAD Deficiency Chorioretinopathy	14:22 - 14:25
14:30 - 15:00	Poster Session 6	Poster 51 - 59				
15:00 - 16:00	Session 9	Retinal diseases Surgical techniques		Chairpersons:	Nicoline Schalijs-Delfos (Netherlands) Chetan K. Patel (United Kingdom) Miklos Resch (Hungary)	
			L 23	Chien WONG (United Kingdom)	Acute Stage 4 Retinopathy of Prematurity: UK National Outcomes of Combined Endoscopic and Conventional Vitrectomy	15:00 - 15:20
			V 1	Krisztian Nagy (Hungary)	Surgical treatment of rare facial clefts – A Case Report	15:20 - 15:28
			V 2	Daniel Jackson (United Kingdom)	Vitrector Pupiloplasty in young children with small or ectopic pupils	15:28 - 15:36
			V 3	Miklos Resch (Hungary)	Pediatric vitrectomy in crystalline lens dislocation	15:36 - 15:44
			RF 35	Bettina Tabori (Hungary)	Foveal avascular zone and macular vessel density in eye of healthy children	15:44 - 15:47
			RF 36	Dora Somodi (Hungary)	OCTA findings in patients with Stickler syndrome compared to normal population	15:47 - 15:50
			RF 37	Daniel Jackson (United Kingdom)	Diagnosing retinal laser injuries using near-infrared autofluorescence	15:50 -15:53
			RF 38	Eleni Papageorgiou (Greece)	Multimodal retinal imaging in pediatric traumatic maculopathy	15:53 -15:56
			RF 39	Malandain Edouard (France)	Macular OCT in Early-Onset Severe Retinal Dystrophies	15:56 -15:59
16:00 - 17:00	Awards. Presentation for next year. Closing Remarks.					

■ Lecture Abstracts
 ■ Free Paper Abstracts
 ■ Rapid Fire Abstracts
 ■ Poster Session
 ■ Round Table
 ■ Video presentations

Lecture Abstracts





8th September 2018

- L 1 Miklós Szabó (Hungary):** Hypoxia induced encephalopathy - neonatology
- L 2 Gábor Rudas (Hungary):** The role of MRI in the diagnosis of neonatal asphyxia
- L 3 Nicoline Schalijs-Delfos (Netherlands):** Retinal Oximetry in a pediatric population
- L 4 Irene Gottlob (United Kingdom):** Normal and abnormal foveal and optic nerve development in infancy
- L 5 Kristina Irsch (USA, France):** Basic principles of state-of-the art ophthalmic imaging technology
- L 6 Nikolaos Ziakas (Greece):** Efficacy and safety of interventions to control myopia progression in children: An overview of systematic reviews and meta-analyses
- L 7 Göran Darius Hildebrand (United Kingdom):** Surgical Strategies for the Correction of Aphakia in Childhood
- L 8 Marie-José Tassignon (Belgium):** The retrolenticular space revisited using intraoperative OCT
- L 9 Annegret Dahlmann-Noor (United Kingdom):** Imaging of trabecular meshwork
- L 10 John Brookes (United Kingdom):** Surgical Aspects in Paediatric Glaucoma
- L 11 Neil Lagali (Sweden):** Imaging of the Ocular Surface in Congenital Aniridia
- L 12 Matthieu P. ROBERT (France):** Retinal Imaging in Sickle Cell Disease
- L 13 Francis L. Munier (Switzerland):** Imaging in Retinoblastoma Management
- L 14 Francesco Puccinelli (Switzerland):** Intra-Arterial Chemotherapy in Retinoblastoma

9th September 2018

- L 15 Eric Arnaud (France):** Orbital distraction for faciocraniosynostosis
- L 16 Pim de Graaf (Netherlands):** Imaging in paediatric orbital tumours
- L 17 Graham E Quinn (USA):** Telemedicine in ROP
- L 18 Birgit Lorenz (Germany):** Imaging of the ocular vasculature in prematures
- L 19 Anna Molnar (Sweden):** The macular region in preterm children
- L 20 Susmito Biswas (United Kingdom):** Nephropathic Cystinosis: Looking beyond the Crystals
- L 21 Cassiman Catherine (Belgium):** Imaging in NF1
- L 22 CK Patel (United Kingdom):** Imaging in paediatric retina
- L 23 S. Chien Wong (United Kingdom):** Acute Stage 4 Retinopathy of Prematurity: UK National Outcomes of Combined Endoscopic and Conventional Vitrectomy



Lecture Abstracts

L 1

Hypoxia induced encephalopathy - neonatology

Miklós Szabó

1st Department of Pediatrics, Semmelweis University, Budapest, Hungary

Speaker: Miklós Szabó





L 2

The role of MRI in the diagnosis of neonatal asphyxia

Gábor Rudas

MR Research Centre, Semmelweis University, Budapest, Hungary

Speaker: Gábor Rudas

Objectives: asphyxia is one of the most common (incidence: 0.3%) and most severe diseases in neonatology with a very short therapeutic window of 6 hours. According to current practice, the diagnosis is based on clinical signs and the therapy is cooling.

The main questions are:

- (1) whether clinical examinations alone possess enough sensitivity and specificity to provide reliable diagnosis of asphyxia?
- (2) Could MRI be the proper tool to distinguish real acute asphyxia (acute: the insult was within the therapeutic window /6 hours/, when cooling is indicated) from other diseases (when cooling is unreasonable).

Conclusion: taken together in 48 (31%) patients cooling was unreasonable. Our findings underline the important role of acute MRI in improving the accuracy of diagnosis and differential diagnosis of neonatal asphyxia. The optic radiation is involved in 90% of the patient in case of the mild or serious Hypoxic-ischaemic encephalopathy.



Lecture Abstracts

L 3

Retinal Oximetry in a pediatric population

Nicoline Schalij-Delfos, Wouter Vehmeijer

Department of Paediatric Ophthalmology, Leiden University Medical Center, Leiden, The Netherlands

Speaker: Nicoline Schalij-Delfos

Retinal oximetry is an imaging technique, which utilizes the difference in light absorption of hemoglobin at different wavelengths of light to determine the relative oxygen saturation of the blood in the retinal vessels. It uses the difference in light absorption of hemoglobin bound and unbound to an oxygen molecule. Dual wavelength retinal oximetry uses two images simultaneously obtained in two different wavelengths. One wavelength is sensitive and the other wavelength is insensitive to changes in oxygen saturation. The difference between the light reflections of highly oxygenated hemoglobin in arteries and in less-oxygenated hemoglobin in venules allows for a measurement of the saturation of the retinal vessels. The software used to calculate these saturation values also determines vessel width.

Various studies on retinal oximetry in adults have been performed. These studies have increased insight in the pathophysiology of common ocular diseases such as central retinal vein occlusion, branch retinal vein occlusion, central retinal artery occlusion, diabetic retinopathy, retinitis pigmentosa and glaucoma. Oxygen plays a key role in several pediatric ocular disorders, for example those involving abnormal vessel development or neovascularization. Increasing the knowledge of saturation levels within the retinal vessels of the eye should provide more insight in potentially blinding pediatric retinal diseases.

Currently, this technique has been scarcely applied to a pediatric population as the current tool to perform oximetry is an application mounted to a fundus camera. Retinal oximetry has been performed in full term infants with the Scanning Laser Ophthalmoscope, The Optomap 200Tx (Optos, UK), proving retinal oximetry can be performed in newborn infants. However, this camera has several disadvantages, preventing easy use in a pediatric population. To make this imaging technique available for a large pediatric population a prototype handheld, mobile retinal oximeter (Corimap camera) has been developed according to the necessary dual-wavelength principles and matching technical specifications. This non-contact camera uses near-infrared light for alignment of the retina and 2 light flashes to capture the images. It can be used in upright and supine position and is applicable to infants of all ages.

This prototype camera is now in use to study retinal oximetry in Retinopathy of Prematurity (ROP). Insight in oxygen saturation of the retina and vessel width supposedly will create opportunities to objectively monitor development of retinal hypoxia in ROP phase 1 and 2 and plus disease of the retinal vessels. The direct monitoring of retinal oxygen metabolism by oximetry allows more precise measurements of blood oxygen saturation and provides opportunities to evaluate the direct effects of supplemental oxygen application or medication to the eye. Apart from ROP, children with Coats disease are under study to search for alarm signs for activation of disease.



Thus, this technique can help to increase the understanding of the pathophysiology of retinal diseases, resulting in opportunities for earlier detection, better monitoring, management and treatment of retinal diseases such as ROP.

References: Magnusdottir V, Vehmeijer WB, Eliasdottir TS, Hardarson SH, Schalijs-Delfos NE, Stefánsson E. Fundus imaging in newborn children with wide-field scanning laser ophthalmoscope. *Acta Ophthalmol.* 2017 Dec;95(8):842-844. doi: 10.1111/aos.13453. Epub 2017 Apr 9.

Vehmeijer WB, Magnusdottir V, Eliasdottir TS, Hardarson SH, Schalijs-Delfos NE, Stefánsson E. Retinal Oximetry with Scanning Laser Ophthalmoscope in Infants. *PloS one* 2016;11:e0148077.

Patel CK, Fung TH, Muqit MM, et al. Non-contact ultra-widefield imaging of retinopathy of prematurity using the Optos dual wavelength scanning laser ophthalmoscope. *Eye (London, England)* 2013;27:589-596.

Vehmeijer WB, Jonkman K, Hardarson SH, Dahan A, Aarts LP, Stefánsson E, Schalijs-Delfos NE. Handheld Retinal Oximetry in Healthy Young Adults. *Translational Vision Science & Technology* in press



Lecture Abstracts

L 4

Normal and abnormal foveal and optic nerve development in infancy

Irene Gottlob

Department of Neuroscience, Psychology and Behaviour, The University of Leicester Ulverscroft Eye Unit, Leicester, United Kingdom

Speaker: Irene Gottlob

Hand-held OCT (HH-OCT) has recently played an increasing role in the clinical evaluation of infants and young children. HH-OCT can be used in young children from birth, is rapid (less than 2 seconds) and contactless and can be used without mydriasis. It allows to investigate the normal development of the fovea and optic nerve. We have shown fast reduction of inner retinal layers and increasing thickness of outer layers in the fovea in the first two years of life and steady increase of optic nerve growth relative to eye growth. HH-OCT allows rapid differential diagnosis of nystagmus aetiology and diagnosis of early onset retinal dystrophies. Grading of foveal hypoplasia in nystagmus enables prediction of visual acuity later in life. Foveal changes also occur in prematurity, in optic nerve diseases and microcephaly. HH-OCT has high sensitivity and specificity in diagnosing optic nerve diseases such as glioma, childhood glaucoma and optic nerve hypoplasia. In conclusion, HH-OCT is a clinically useful technique to identify retinal and optic nerve disease in early childhood and patients who cannot co-operate with standard table mounted devices.



L 5

Basic principles of state-of-the art ophthalmic imaging technology

Kristina Irsch

The Wilmer Eye Institute, The Johns Hopkins University School of Medicine, Baltimore, USA
Institut de la Vision, Sorbonne-University, Paris, France

Speaker: Kristina Irsch

This lecture is aimed at providing an overview of the optical principles of various state-of-the-art ophthalmic instruments. The goal is to illuminate for the clinician and scientist the underlying concepts and principles of various devices, even when not familiar with the particular technology employed within the instrument. For example, the basic principles of scanning laser ophthalmoscopy, optical coherence tomography, as well as adaptive optics will be presented, with a discussion of cutting-edge technological developments and notable applications in ophthalmology.



Lecture Abstracts

L 6

Efficacy and safety of interventions to control myopia progression in children: An overview of systematic reviews and meta-analyses

Nikolaos Ziakas, Efthymia Prousali, Anna-Bettina Haidich, Andreas Fontalis, Periklis Brazitikos, Asimina Mataftsi

Aristotle University of Thessaloniki, Thessaloniki, Greece

Speaker: Nikolaos Ziakas

Myopia is a common visual disorder with increasing worldwide prevalence. Halting progression of myopia at an early stage is critical, as high myopia can be complicated by a number of vision-compromising conditions. We conducted an overview of systematic reviews (SRs) and meta-analyses (MAs) in order to identify and appraise robust evidence regarding the management of myopic progression in children.

According to our results atropine eyedrops, orthokeratology and multifocal SCLs demonstrate efficacy in myopic progression control. Associated adverse events have prevented these interventions from becoming widely accepted for myopia treatment. The most common are photophobia, mydriasis, cycloplegia, rebound effect for atropine, and microbial keratitis for orthokeratology.

Future research geared towards effective interventions could provide insight into the appropriate regimes for administration of these modalities and identify potential long-term complications, contributing to guideline development.



L 7

Surgical Strategies for the Correction of Aphakia in Childhood

Göran Darius Hildebrand

Oxford Eye Hospitals, University of Oxford, Oxford, United Kingdom

Speaker: Göran Darius Hildebrand

Paediatric lens removal surgery for ectopia lentis and cataracts, especially in infancy, may result in secondary aphakia. Non-surgical management with glasses and contact lenses can yield very rewarding results for the child and the family, but may not be a permanent solution due to non-compliance, intolerance or patient choice.

Surgical options for the correction of aphakia include secondary IOL implantation with bag, sulcus (with and without optic capture), iris (pre- and post-pupillary), scleral (sutured, tunneled and glued) as well as Bag-in-the-Lens fixation techniques.

All these techniques provide now a wide range of surgical options for the surgical correction of aphakia in childhood with their own special intra- and post-operative challenges.



Lecture Abstracts

L 8

The retrolenticular space revisited using intraoperative OCT

Marie-José Tassignon

Department of Ophthalmology University Hospital, Antwerp, Belgium

Speaker: Marie-José Tassignon

Anatomists and ophthalmologists of the 17th and 19th century described the retrolenticular interface. No much interest has been given to that space ever since. The bag-in-the-lens technique for cataract surgery is making use of this interface. With the advent of the intraoperative OCT it is currently possible to visualize this space and even to discover new congenital pathologies based on dysgenesis of the anterior hyaloid, the posterior capsule and their attachment.



L 9

Imaging of trabecular meshwork

Annegret Dahlmann-Noor

National Institute for Health Research Biomedical Research Centre at Moorfields Eye, Hospital and University College London Institute of Ophthalmology, London, United Kingdom

Speaker: Annegret Dahlmann-Noor

Over 90% of aqueous outflow occurs via the trabecular meshwork (TM) and Schlemm canal (SC). The laminar beams of the TM, which consist of elastic and collagenous fibres, form a porous structure through which aqueous drains passively. SC is a non-continuous circular tube, lined with endothelial cells; on the TM side, pores allow fast entry of aqueous. From SC, collector channels drain aqueous into the aqueous veins. The juxtacanalicular TM and inner wall of SC appear to be the site of greatest resistance to aqueous outflow.

Since 2010, it has been possible to visualise SC, collector channels and aqueous veins in humans, using optical coherence tomography (OCT). SC diameter varies along the circumference; it is larger on the nasal than on the temporal side. Elevating IOP acutely decreases the cross-sectional area of SC (SC-CSA). Similarly, SC-CSA is reduced in chronic open angle and pseudoexfoliation glaucoma.

New OCT imaging techniques such as a corneal adaptive compensation algorithm allow the visualisation of greater detail at greater depth. In a research setting, post-image acquisition contrast enhancement has recently allowed visualisation of SC, collector channels and aqueous veins along the entire 360 degree circumference. A recent development, phase-sensitive imaging, allows the detection of TM movement. The cardiac pulse causes intraocular pressure oscillations, and ex vivo simulation of this IOP fluctuation can visualise movement of the TM close to SC, followed by changes in SC diameter.

In a clinical setting imaging and volume measurements of the full circumference of SC and collector channels remain a challenge, mainly due to image acquisition time and the limited field of view of individual scans. Similarly, resolution is not sufficient to reliably image the porous structure of the TM.

Aqueous outflow imaging may become useful to test how individual patients respond to IOP-lowering medication, for example pilocarpine and travoprost, as it can demonstrate structural changes such as SC widening within minutes of application. Imaging may also be used to visualise the effect of surgical interventions such as canaloplasty, trabeculectomy and phacoemulsification, which induce widening of SC. As a research tool, OCT imaging of the aqueous outflow may reveal mechanisms of intraocular pressure regulation and the mechanism of action of current and future medications. Our group has studied the effect of physiological accommodation on outflow structures. In children, who have a high amplitude of accommodation, intense accommodative effort and ciliary muscle contraction leads to a marked increase in SC-CSA. In children who have undergone lensectomy, SC-CSA is smaller than in healthy eyes. In addition, the dynamic increase in SC-CSA with accommodative effort is reduced or absent, even though ciliary muscle contraction is normal, indicating that lensectomy disrupts the transmission of ciliary muscle pull onto the trabecular meshwork and the inner wall of SC. Further work is required to investigate how this mechanical disruption of SC dynamics contributes to the development of post-lensectomy glaucoma.



Lecture Abstracts

L 10

Surgical Aspects in Paediatric Glaucoma

John Brookes

Moorfields Eye Hospital & Great Ormond Street Hospital for Children, London, United Kingdom

Speaker: John Brookes

Childhood glaucoma is a lifelong condition, most children eventually needing surgery. For many decades, goniotomy surgery has been first line treatment for primary congenital glaucoma (PCG), initially reported in 1942. Since the 1960's, trabeculotomy has also been employed in PCG with similar surgical outcomes. In more recent years, the 360 degree trabeculotomy has improved outcomes significantly and in many cases is now first choice in PCG. However, angle surgery is sometimes not effective and also not appropriate in secondary glaucomas. Therefore, this talk will look at the surgical aspects of 360 degree trabeculotomy in PCG and also options after failed angle surgery and surgical choices in secondary glaucomas, especially glaucoma drainage implants.



L 11

Imaging of the Ocular Surface in Congenital Aniridia

Neil Lagali

Linköping University, Linköping, Sweden

Speaker: Neil Lagali

The cornea in congenital aniridia is characterized by a progressive stem cell deficiency leading to breakdown of the limbal stem cell niche followed by conjunctivalization of the ocular surface called aniridia-associated keratopathy (AAK). The congenital malformation of the cornea, iris, and lens are often visible upon birth; however, detailed examinations of the anterior segment including the corneal morphology are difficult. Here we present an imaging protocol for examining the anterior segment in young children from several months of age through the first decade of life. Detailed imaging is performed with or without general anesthesia, to document the pattern and extent of anterior segment pathology in aniridia. Using a combination of anterior segment optical coherence tomography, photography and in vivo confocal microscopy, a detailed picture of the ocular surface can be gained that can aid in prognosis and treatment decisions.



Lecture Abstracts

L 12

Retinal Imaging in Sickle Cell Disease

Matthieu P. Robert

Hôpital Necker - enfants malades, AP-HP, Paris, France

Speaker: Matthieu P. Robert

Sickle-cell disease (SCD), with its three phenotypes: SS, SC and the rarer S beta thalassemia, is the most commonly diagnosed genetic disorder in the world. The retina is a unique target of the disease, with the SC phenotype being the main provider of serious retinal complications, potentially sight-threatening, while it is the least severe from a systemic point of view.

Ophthalmological screening in SCD has therefore long focused on the peripheral retinopathy classified by Goldberg. Current recommendations are based in this specific risk - a systematic yearly examination from age 6 in SC SCD and from age 10 in SS SCD and S beta thalassemia. Besides conventional fundus photographs, the usual difficulty to visualize the retinal periphery in children has led to perform fluorescein angiography more often than in adults. Wide-field fundus photographs are currently overwhelming the habits in peripheral SCD retinopathy screening and management. Imaging has become crucial in the follow-up and treatment of SCD peripheral retinopathy.

A series of studies have recently cast light on another, long known though neglected manifestation of the disease: SCD maculopathies. Two distinct types can be distinguished: classical, rare, acute losses of vision secondary to a macular ischemia in children with SS SCD; very frequent, asymptomatic paramacular retinal atrophies usually centered by the median temporal raphe, in children with all SCD genotypes. These peculiar areas of retinal atrophy are revealed by SD-OCT; their functional meaning and mechanisms are still currently a matter of debate.

Retinal imaging is helpful for clinicians following children with SCD and for research, where much remains to be understood in the natural history and pathophysiology of the disease.



L 13

Imaging in Retinoblastoma Management

Francis L. Munier

Jules-Gonin Eye Hospital, Lausanne, Switzerland

Speaker: Francis L. Munier

At diagnosis, management of retinoblastoma is determined by grouping and staging of disease as assessed by fundus photography and mainly resonance magnetic imaging respectively. During conservative management, therapeutic strategy is continuously challenged by tumor response and treatment-related complications. The fine tuning in decision making increasingly relies on ancillary imaging techniques, such as fluorescein angiography (FA), optic coherence tomography (OCT) and ultrasonic biomicroscopy (UBM). We will show that these imaging modalities are instrumental in the infraclinical detection and monitoring of tumoral and non-tumoral events, and thus have a profound impact on the treatment strategy and the final clinical outcome.



Lecture Abstracts

L 14

Intra-Arterial Chemotherapy in Retinoblastoma

Francesco Puccinelli

Lausanne University Hospital, Lausanne, Switzerland

Speaker: Francesco Puccinelli

Several invasive treatment options have been developed for retinoblastoma. Focal therapies, such as laser therapy, cryotherapy and thermotherapy, are often used alone or in conjunction with other treatment modalities.

In 2004 Yamane et al. [1] published the safety and feasibility of selective ophthalmic artery infusion by placing a guiding catheter in the cervical segment of the internal carotid artery with a balloon distal to the ostium of the ophthalmic artery. The balloon subsequently inflated to divert a Melphalan infusion directly into the ophthalmic artery.

In 2008, Abramson et al. [2] modified the selective ophthalmic artery infusion technique to allow for super-selective catheterization of the ophthalmic artery, infusing chemotherapy directly through the micro catheter. Via a transfemoral approach, a microcatheter is visualized and directed under digital subtraction angiographic guidance to super-selectively catheterize the origin of the ophthalmic artery.

Frequently, for anatomical reasons, alternative arterial routes must be used, such as selective catheterisation of branches of external carotid artery to delivery chemotherapy via anastomoses with ophthalmic artery. Also, navigation through the posterior communicating artery to catheterize more directly and easily the ophthalmic artery.

Possible complications of intra-arterial chemotherapy are related minimally invasive nature of this particular technique which employs more potent drug concentrations compared to those used in systemic chemotherapy. The most common complications are lid or periocular oedema and/or redness (28.5%), ptosis (5.6%), vitreous haemorrhage (3.3%), periocular erythema (3.0%), chorioretinopathy (2.8%), and dermatological rash (2.5%).



L 15

Orbital distraction for faciocraniosynostosis

Eric Arnaud

Center of reference for rare diseases in Hopital Necker Enfants Malades, Paris, France
President of the International Society for Craniofacial Surgery (ISCFS)

Speaker: Eric Arnaud

Faciocraniosynostosis is the combination of skull, orbits and facial malformations, resulting in exorbitism (shallow orbit) and apnea syndrome, as well as raised intracranial pressure. The growth disturbances in the skull and face being variable according to the type of mutation in the FGFR (Crouzon, Pfeiffer, Apert), the strategy is adapted to the phenotype according to the following principles : Posterior skull expansion with or without distraction around 6 months to limit the descent of the cerebellum tonsils and to prevent the turricephalic development ; Fronto-facial monobloc advancement with internal distraction around the age of 18 months in case of severe exorbitism or breathing impairment, in order to correct exorbitism and facial retrusion. The dissociated strategy (fronto-orbital advancement first, followed by facial osteotomy of Le Fort 3 type) is also an alternative. The growing evolution dictates the sequence of subsequent surgeries according to the monitoring of intracranial pressure by fundus examination and OCT, and of the respiration by polysomnography. Le Fort 3 and transversal maxillary distraction may be repeated if necessary. Orthognathic surgery is almost always compulsory after the age of 14, before the aesthetic refinements which can be undertaken ultimately (rhinoplasty, genioplasty, canthopexies, fat grafting..). The complexity of treatment of faciocraniosynostosis justifies the treatment in a reference center for rare diseases, which concentrates a true multidisciplinary team. CRM CRANIO (Hop. Necker Enfants Malades) belongs to the ERN (European Reference Network) which coordinates the european centers.



Lecture Abstracts

L 16

Imaging in paediatric orbital tumours

Pim de Graaf

Amsterdam UMC, Amsterdam, The Netherlands

Speaker: Pim de Graaf

The spectrum of tumours and tumour-like lesions of the orbit in children differs from that in adults. Also the distribution of benign vs malignant tumours varies between paediatric age groups. In newborns and young infants, vasculogenic lesions are the most common primary orbital mass lesions, whereas life-threatening malignant lesions become more prevalent in older age groups. Most of the orbital masses typically manifest with proptosis, and imaging differentiation is desirable because the treatments and prognoses vary greatly.

Rhabdomyosarcoma is the most common orbital tumour of childhood. This neoplasm grows quite rapidly, and is fairly vascular. The clinical presentation and imaging characteristics are presented.

Infantile haemangioma, a true neoplasm, and venous-lymphatic malformation, a developmental anomaly are the two most common vascular lesions in the paediatric patient. Haemangioma is quite vascular, has a predictable course of proliferation followed by slow involution, and is distinguished on magnetic resonance (MR) images by the finding of flow voids within the mass and at its periphery. Venous-lymphatic malformation in the orbit is an anomaly of venous and lymphatic development that is characterized by unenhancing, cystic lymphatic and enhancing, solid venous components. Intralesional haemorrhage is common and can cause an acute worsening of clinical symptoms and presents with distinctive fluid-fluid levels within the cystic portions on MRI. Unlike haemangiomas, venous-lymphatic malformations grow with the patient and never involute spontaneously.

1. The imaging features of the most common orbital masses in children are described.
2. Features of orbital masses that may allow differentiation from other orbital tumours in children are presented.
3. The differential diagnosis of orbital masses and management of paediatric patients with these conditions are briefly discussed.



L 17

Telemedicine in ROP

Graham E. Quinn

Division of Ophthalmology, The Children's Hospital of Philadelphia, Philadelphia, USA

Speaker: Graham E. Quinn

There is a growing consensus of the utility of telemedicine in infants at ROP risk, and steps toward validation of such a program need to be systematically developed. The shift away from clinical examination by an ophthalmologists to using digital images to determine the need for an ROP examination has several advantages: the extension of ROP surveillance to regions in which examination by experienced ophthalmologists is limited; standard grading protocols; and improved imaging systems will likely enable a more reproducible and reliable provision of care to at-risk infants.



Lecture Abstracts

L 18

Imaging of the ocular vasculature in prematures

Birgit Lorenz

Dept. of Ophthalmology, University of Giessen, Germany, Universitaetsklinikum Giessen and Marburg UKGM GmbH, Giessen Campus, Giessen, Germany

Speaker: Birgit Lorenz

Rationale: Prematures at risk for acute retinopathy of prematurity ROP may have an abnormal vascular development with and without acute ROP. Newer imaging modalities allow its visualisation. Recent results from the Giessen ROP Imaging Group GRIP will be presented.

Methods and Results: Retinal wide-field imaging including telemedicine has the potential to objectively compare inter observer classifications, and questions binocular indirect ophthalmoscopy (BIO) as the gold standard. Fluorescein angiography (FA) has opened a new field of evaluating the extent of vascularisation including avascular zones central to the peripheral vascularisation border. In addition, FA visualizes the degree of vascular leakage which is particularly intense in aggressive posterior ROP APROP and also macular edema that may be present even in milder forms of ROP. FA also visualizes long-term vascular abnormalities and persistent peripheral avascularity. Hand-held spectral-domain optical coherence tomography (hh- SD-OCT) discloses new features such as macular oedema and macular immaturity that may later translate into macular developmental arrest MDA responsible in part for reduced visual function despite regression of acute ROP. The choroid also displays changes. OCT angiography (OCT-A) remains extremely challenging in acute ROP. OCT-A is possible from the age of about 4y on when a child can fixate steadily on although still challenging. In case of MDA a smaller than normal superficial foveal avascular zone FAZ can be visualized while the deep FAZ remains normal. All vascular changes described are important as to follow-up and visual prognosis.

Conclusion: Evolving imaging tools allow a precise evaluation of the retinal and choroidal vasculature in prematures, both in the acute stage and at follow-up.

References:

Bowl W et al., IOVS 2016

Bowl W et al. Klin. Mnbl. Augenheilkd. 2016

Bowl W et al., Ophthalmic Research 2018

Bowl W et al., Ophthalmology Retina 2018

Lorenz B et al., Retina 2017



L 19

The macular region in preterm children

Anna Molnar

Department of Paediatric Ophthalmology, St Eric Eye Hospital, Stockholm, Sweden

Speaker: Anna Molnar

Important histological steps in macular development take place at 24-25 weeks of gestational age, during which the foveal pit appears and the foveal avascular zone is created. Macular development continues a long time after birth, but the exact length of time for final maturation is unknown. The postnatal development of the macular region has been studied with spectral domain OCT and delayed photoreceptor maturation has been reported. The structural abnormalities of the macula appears to persist later into childhood, where several OCT-studies reveal significantly thicker central macula in comparison to children born at term. The cause of the thicker central macula seems to be an incomplete migration of the inner retinal layers. Low GA and ROP has been identified as important risk factors for a thick central fovea. No significant association between visual acuity and the central macular thickness has been found. However, reduced multifocal-ERG responses in school-aged prematurely born children is reported.



Lecture Abstracts

L 20

Nephropathic Cystinosis: Looking beyond the Crystals

Susmito Biswas

Manchester Royal Eye Hospital, Manchester Foundation Trust and University of Manchester, Manchester, United Kingdom

Speaker: Susmito Biswas

Nephropathic Cystinosis is a rare autosomal recessive lysosomal storage disorder caused by accumulation of intracellular cystine due to defective function of cystinosin, a lysosomal membrane transport protein encoded by the gene CTNS. Crystal deposition importantly occurs in the eyes resulting in a variety of complications. Of these the most characteristic are deposition of crystals in the cornea. These give rise to symptoms of glare, irritation and photophobia. Progressive crystal deposition can result in sight threatening complications, including a pigmentary retinopathy. In addition other complications such as raised intracranial pressure may be first detected by ophthalmologists.

The role of the ophthalmologist in the management of cystinosis is therefore a key component of the multidisciplinary care of patients with this disorder. The Manchester Cystinosis MDT comprises an ophthalmologist, nephrologist and endocrinologist undertaking a comprehensive review of renal, ocular and endocrine management of children and young people with cystinosis. A structured approach is used to ascertain symptoms, compliance with treatment and monitoring of ocular features. The role of anterior segment imaging and posterior segment imaging modalities to complement clinical assessment will be discussed with cases presented from the MDT clinics.



L 21

Imaging in NF1

Cassiman Catherine

University Hospital, Leuven, Belgium

Speaker: Cassiman Catherine

Neurofibromatosis type 1 (NF1) is a very common genetic disorder. Due to a mutation of the tumor suppressor protein 'neurofibromin', patients are prone to develop both benign and malignant tumors. The ophthalmological manifestations of NF1 are Lisch nodules, plexiform neurofibroma of the upper lid with concurrent glaucoma and sphenoid deformation and optic pathway glioma (OPG). For timely detection of these lesions, children with NF1 undergo regular ophthalmological screening. The newest imaging tools such as OCT and MRI modalities are employed as biomarkers for vision in the screening for OPG. In this presentation, the age dependent prevalence and the appropriate documentation of these 3 ophthalmological symptoms will be discussed, together with a (likely) new diagnostic sign for NF1 namely 'choroidal nodules'.



Lecture Abstracts

L 22

Imaging in paediatric retina

CK Patel

Oxford University, Oxford, United Kingdom

Speaker: CK Patel





L 23

Acute Stage 4 Retinopathy of Prematurity: UK National Outcomes of Combined Endoscopic and Conventional Vitrectomy

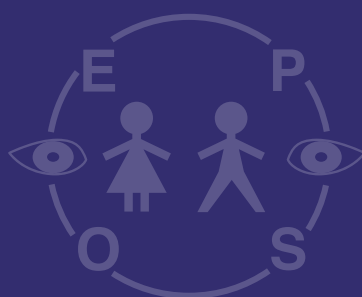
S. Chien Wong

Great Ormond Street Hospital for Children, NIHR Biomedical Research Centre, Moorfields Eye Hospital & UCL Institute of Ophthalmology and Royal Free Hospital, London, United Kingdom

Speaker: S. Chien Wong

Surgery for acute stage 4 retinopathy of prematurity is complex, requiring primary lensectomy in up to 57% in published data. This talk discusses the benefits of an alternative approach of combining endoscopic vitrectomy with standard microscope visualisation techniques during vitrectomy. Results from the UK national ROP retinal detachment, Great Ormond Street Hospital for Children (London, UK), will be presented by Dr Wong, which demonstrated 0% primary lensectomy in over 50 consecutive stage 4A and 4B eyes.

Round Table





Round Table on Optic Disc Drusen

Moderator: Göran Darius Hildebrand (United Kingdom)

Panelists:

Irene Gottlob (United Kingdom)

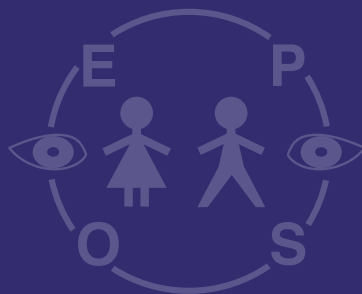
Lasse Malmqvist (Denmark)

Cameron Parsa (USA)

Guenther Rudolph (Germany)

The aim of this new format is to explore the common topic of optic disc drusen. The moderator will pose questions to the panel to stimulate discussion and commentary around the following areas: epidemiology, pathogenesis, clinical presentation, differential diagnosis, diagnostic work-up (what's the role of B scan, conventional and enhanced depth imaging OCT, autofluorescence, multi-disciplinary involvement and neuroimaging), complications and their management (are there topical medication, intravitreal anti-VEGF and vitreoretinal options in severe disease?). Each panelist will be asked to give key take home messages at the end.

Free Paper Abstracts





8th September 2018

- FP 1 Jose Torres-Peña (Spain):** Idiopathic intracranial hypertension in pediatric population
- FP 2 Zhanhan Tu (United Kingdom):** Optical Coherence Tomography Provides Insights into the Pathology of Cerebral Malaria
- FP 3 Annegret Dahlmann-Noor (United Kingdom):** Myopia increase in London - progression rate similar in children of different ethnic backgrounds and faster in girls
- FP 4 Huda Al-Hayouti (United Kingdom):** Meibography and corneal volume optical coherence tomography to quantify damage to ocular structures in children with blepharokeratoconjunctivitis
- FP 5 Annegret Dahlmann-Noor (United Kingdom):** Childhood lensectomy: associated with an arrest in foveal development
- FP 6 Christopher Lloyd (United Kingdom):** Glaucoma following surgery for congenital cataract
- FP 7 Christina Stathopoulos (Switzerland):** Simple, double and triple cloud in retinoblastoma: role of dynamic B-scan ultrasonography

9th September 2018

- FP 8 Amit Chhabra (United Kingdom):** Apraclonidine in diagnosis of Partial Horner Syndrome in children
- FP 9 Kasia Trzcionkowska (Netherlands):** Treatment of Retinopathy of Prematurity in the Netherlands between 2010-2016
- FP 10 Kerstin Hellgren (Sweden):** Visual cognitive problems captured with a structured history inventory in extremely preterm born children aged 6.5 years
- FP 11 Eva Larsson (Sweden):** Visual function is reduced in formerly prematurely born young adults - a population-based study
- FP 12 Urszula Kulik (Sweden):** Optical coherence tomography in the evaluation of children with neurofibromatosis type 1
- FP 13 Cameron F. Parsa (France):** Brushfield spots and Wölfflin nodules unveiled in dark irides using near-infrared light



Free Paper Abstracts

FP 1

Idiopathic intracranial hypertension in pediatric population

Jose Torres-Peña, Celia Martinez-Vazquez,
Pilar Tejada-Palacios, Cristina Lopez-Lopez,
Noemi Nuñez-Enamorado,
Ana Martinez-De-Aragon

Hospital Universitario 12 De Octubre, Madrid, Spain

Speaker: Jose Torres-Peña

Introduction: Idiopathic intracranial hypertension (IIH) is a condition in which there are signs of increased intracranial pressure without presenting an obvious cause in the imaging tests or in the study of cerebrospinal fluid (CSF).

In adults there is an established association between obesity and IIH, however, this association is weak in the pediatric population where only 30% seem to be overweight, therefore, a series of possible underlying causes have been identified, such as endocrinopathies, medication, viral infections, nutritional etiology or systemic conditions.

Methods: We performed a retrospective study of 22 children with an IIH diagnosis at the Hospital Universitario 12 de Octubre (Madrid) between February 2007 and September 2016. The demographical, clinical, and ophthalmological data at the beginning and at the end of their treatment was collected as well as the follow up with OCT.

Results: The 22 patients were in the 2-14 age range, with 40.9% of the children in the 10-13 range. Among these patients, 59.09 % were females and 40.91% were males. Regarding the weight, 47.6% of the patients had normal weight and 52.4% were overweight or obese. Headache and diplopia were the most common symptoms. In ophthalmological examination, 19 patients (86.36%) had acute papilledema and 1 patient had a chronic papilledema (4.54%). There was a significant correlation between the cerebrospinal fluid (CSF) pressure and the peripapillary retinal nerve fiber layer (RNFL) measured in the OCT. After treatment, visual acuity improved statistically significantly. Only 3 patients had a poor visual outcome, 2 patients had a visual acuity loss, while 1 patient had a motility dysfunction.

Conclusion: Knowledge of the clinical presentation of IIH in children is essential in order to start treatment and avoid poor visual outcome. New tools like OCT could help in diagnosing IIH.

FP 2

Optical Coherence Tomography Provides Insights into the Pathology of Cerebral Malaria

Zhanhan Tu¹, Jack Gormley², Simon Harding²,
Karl Seydel³, Terrie Taylor³, Irene Gottlob¹

¹ Ulverscroft Eye Unit, Department of NPB,
University of Leicester, United Kingdom

² Department of Eye and Vision Science, University
of Liverpool, United Kingdom

³ College of Osteopathic Medicine, Michigan State
University, USA

Speaker: Zhanhan Tu

Introduction: Cerebral malaria (CM), the most severe complication of malarial infection, causes death in approximately 15-25% of cases, the majority of whom are children. Clinical signs of malaria retinopathy (MR) not only help to detect CM but also to predict severity. This study, for the first time, investigated in vivo retinal features of CM using hand-held spectral domain optical coherence tomography (HH-OCT) to evaluate the potential of HH-OCT to improve diagnosis and management.

Methods: 52 children with CM (MR positive n=43 and negative n=9) were recruited. On admission, examinations included: cerebrospinal fluid opening pressure (CSF-OP), dilated fundus examination, colour fundus photography and fluorescein angiography. If possible HH-OCT was performed daily during admission, at one month and one year. Thicknesses of retinal layers and volumetric optic nerve head (ONH) and peripapillary retinal nerve fibre layer were measured.

Results: In CM positive patients, retinal vessels with abnormal hyper-reflective walls and variable lumina (72.6% hypo-reflective, 83.9% hyper-reflective) were found. We also found hyper-reflective capillaries corresponding to capillary plexi. Hyper-reflective areas in the inner retina (81.4%), cotton wool spots (37.2%), haemorrhages (36%) and cystoid macula oedema (9.3%) were seen. Histological comparison suggests large vessels with hyper-reflective walls correspond to vessels with parasitized erythrocytes sequestration. Vascular changes resolved within 48 hours after treatment. Hyper-reflective areas were still present 1-month post-discharge and coincided with atrophy. HH-OCT scans allowed detection of MR signs such as hyper-reflective capillaries and vessels in 7 out of 9 MR negative CM patients. CSF-OP had strong positive correlations with ONH rim volume ($p=0.0002$) and rim area ($p=0.002$). Maximum cup depth ($p=0.01$), cup volume ($p=0.02$), cup/disc ratio ($p=0.002$) and cup area ($p=0.012$) were negatively correlated with CSF-OP.

Conclusion: OCT, for the first time, appear to demonstrate parasitised erythrocytes sequestering on the endothelial vessel walls. It can also detect subclinical retinal changes in patients with CM. HH-OCT changes in MR have the potential to identify children needing more intense treatment and monitor parasite clearing during treatment. As a non-invasive, highly repeatable and rapid test, ONH parameters on HH-OCT scan may be useful biomarkers and alternative to lumbar punctures for management of CM patients.



FP 3

Myopia increase in London - progression rate similar in children of different ethnic backgrounds and faster in girls

Annegret Dahlmann-Noor, Karen Wong

NIHR Biomedical Research Centre at Moorfields Eye Hospital, London, United Kingdom

Speaker: Annegret Dahlmann-Noor

Background/Aims: Worldwide, the prevalence of myopia is increasing. Myopia now begins at younger ages and progresses faster, leading to more adults with high myopia and risk of sight-threatening complications. No data are available about myopia trends in children in urban areas in the UK. This work presents a 10-year review of children attending a secondary and tertiary eye care facility in London, UK, focussing on prevalence and progression rates.

Methods: We collated refraction and demographic data from children under the age of 17 years seen at Moorfields Eye Hospital, London, UK, between 2007 and 2017.

Results: We included 63,854 datasets from 23,593 children (51.2% boys, median age 5.4 years, interquartile range IQR 3.8 to 7.1). The proportion of myopic prescriptions increased from 24 to 32%, around 1%/year. Of n=3,355 with initial mild/moderate myopia and follow-up data, 2,095 (62%) experienced progression. The median rate of progression was -0.40 (-0.2 to -0.7) D/year, slightly higher in girls (-0.42 D/year, IQR -0.2 to -0.8, n=965) than in boys (-0.38 D/year, IQR -0.2 to -0.7, n=1,130); p=0.02. Progression was faster in initial moderate than initial mild myopia, p<0.001 (median -0.54 vs -0.37 D/year). There was no statistically significant difference before and after the cut-off age set as onset of puberty, nor between children of different ethnic backgrounds.

Conclusions: In this cohort, the prevalence of progressive myopia and the rate of progression are higher than previously reported for European countries. Living in an urban environment may result in similar progression rates despite different genetic backgrounds.

FP 4

Meibography and corneal volume optical coherence tomography to quantify damage to ocular structures in children with blepharokeratoconjunctivitis

**Huda Al-Hayouti¹, Moritz Daniel¹,
Melanie Hingorani², Virginia Calder³,
Annegret Dahlmann-Noor¹**

¹ NIHR Moorfields Biomedical Research Centre, London, United Kingdom

² Paediatric Service, Moorfields Eye Hospital, London, United Kingdom

³ UCL Institute of Ophthalmology, London, United Kingdom

Speaker: Huda Al-Hayouti

Introduction: However, grading systems do not allow quantification of subtle changes, such as corneal thinning, and also do not include MG changes, although these are a core component of BKC. In this study we aimed to evaluate whether new technologies such as non-contact infra-red meibography and anterior segment optical coherence tomography (OCT) would detect changes in children with BKC.

Methods: This was a prospective observational case-control study. We enrolled 31 children with BKC, and 32 healthy volunteers (HV), attending Moorfields Eye Hospital. We used an Oculus Keratograph to acquire meibography images of upper and lower lids and a Tomey Casia 2 for corneal OCT scans of one eye of each participant. We used three grading systems to semi-quantitatively describe MG structure and changes: 1) the "meiboscore" (MG dropout MG in relation to total MG gland area, values 0 to 3 for each lid, total score 0-6 for each eye); 2) full and partial gland dropout (0-2 and 0-3, respectively); 3) distortion of individual glands (0-5). On the corneal OCT, we measured total corneal volume and differential corneal volume per quadrant (nasal, temporal, superior and inferior), and central corneal thickness (CCT).

Results: Meiboscores for upper and lower lids and total Meiboscore were significantly higher in children with BKC than in children without ocular surface inflammation (p < 0.001). Full and partial MG dropouts were also significantly higher in children with BKC than in HV (p < 0.001). There was no difference in MG distortion between children with BKC and HV (p > 0.05). The corneal volume in the superior quadrant was significantly higher in children with BKC than in HV, whereas the corneal volume in the nasal and inferior quadrants was significantly thinner. There was no significant difference in corneal volume in the temporal quadrant, in total corneal volume or in central corneal thickness.

Conclusions: Non-contact imaging technologies can demonstrate damage to Meibomian glands and cornea volume even in mild to moderate BKC. These parameters may be useful both for long-term clinical follow-up and as outcomes in clinical trials.



Free Paper Abstracts

FP 5

Childhood lensectomy: associated with an arrest in foveal development

Annegret Dahlmann-Noor¹, Moritz Daniel¹, Adam Dubis¹, Gillian Adams², Maria Theodorou², Peng Khaw¹

¹ NIHR Moorfields Biomedical Research Centre, London, United Kingdom

² Paediatric Service, Moorfields Eye Hospital, London, United Kingdom

Speaker: Annegret Dahlmann-Noor

Background/Aims: Lensectomy in early childhood is often associated with suboptimal or poor development of visual acuity. In this study, we aimed to explore the impact of childhood lensectomy on posterior segment development.

Methods: We enrolled 45 children age 4 to 16 years with healthy eyes and 40 post-lensectomy, mean (SD) age 11 (3) years, attending clinics at Moorfields, into this cross-sectional observational study. We acquired optical coherence tomography scans of both eyes and obtained measurements of foveal pit depth and subfoveal choroidal thickness; we also analysed inner and outer ring choroidal thickness (IRCT, ORCT) and photoreceptor layer parameters, macular and peripapillary retinal nerve fibre layer thickness (RNFLT). We used SPSS24 (IBM, Armonk, USA) for the comparison of parameters between groups and within individuals, considering a p-value under 0.05 as significant.

Results: Foveal pit depth and subfoveal choroidal thickness are significantly reduced in eyes that have undergone lensectomy compared with non-operated eyes: mean (SD) foveal pit depth 57.6 (25) μ m after lensectomy versus 72.6 (14.3) μ m in healthy eyes; subfoveal choroidal thickness 283.5 (95.9) versus 353.7 (88.4) μ m. IRCT and ORCT are reduced, as are inner ring macular RNFLT and superior/inferior/temporal peripapillary RNFLT. Central retinal thickness, inner retinal and outer nuclear layers are not affected.

Conclusions: Childhood lensectomy may be associated with an arrest in developmental foveal pit deepening and a lack of developmentally normal thickening of the posterior choroid. Mechanical and optical disruption of posterior accommodation may contribute to poor visual outcomes.

FP 6

Glaucoma following surgery for congenital cataract

Christopher Lloyd

Dept. Ophthalmology, Great Ormond Street Hospital, London, United Kingdom

Speaker: I. Christopher Lloyd

Introduction: Bilateral congenital cataract is rare (3/10,000 live births) but remains a common cause of potentially treatable blindness in infancy. The recent IATS and IOLu2 studies confirm that timely and careful surgery is commonly complicated by subsequent glaucoma. Diagnosis is often difficult and is thus often delayed. The aetiology and pathophysiology of aphakic/pseudophakic glaucoma and ocular hypertension are poorly understood but are likely to be multifactorial.

Methods: A series of clinical cases from a tertiary referral centre illustrating aphakic, pseudophakic, pupil block and PFV associated glaucoma following infantile surgery are presented and discussed in the context of IATS and IOLu2.

Results: The IATS study had a 17% glaucoma rate at 4.8 years with a further 14% of operated eyes exhibiting ocular hypertension. Aphakic eyes in the IOLu2 study had an almost identical rate of glaucoma (16%) at 5 years. Increasing age at surgery was found to be protective in both studies.

Published in vitro work has shown changes in cytoskeletal proteins and altered gene expression in immature trabecular meshwork cells exposed to lens epithelial cells. This informs the hypothesis of early surgery disrupting TM differentiation.

Conclusion: Carefully constructed multicentre collaborative studies collating phenotypic and genotypic data will be needed to further stratify the risk of glaucoma and identify best practice.



FP 7

Simple, double and triple cloud in retinoblastoma: role of dynamic B-scan ultrasonography

Christina Stathopoulos¹, Marie-Claire Gaillard¹,
Francesco Puccinelli², Maja Beck-Popovic³,
Francis L Munier¹

¹ Jules-Gonin Eye Hospital, University of Lausanne, Switzerland

² Interventional Neuroradiology Unit, CHUV, Lausanne, Switzerland

³ Unit of Paediatric Hematology-Oncology, CHUV, Lausanne, Switzerland

Speaker: Stathopoulos Christina

Introduction: Retinoblastoma tumor cells can spread into different anatomic compartments (subretinal, retrohyaloidal, intravitreal and intracameral) adopting various morphologic aspects (dust, spheres and cloud). In case of dense seeding, optic nerve view can be totally obscured, making the decision for conservative treatment challenging. We describe different clinical presentations of cloud seeding (class 3 seeding) in retinoblastoma patients and discuss the role of B-scan ultrasonography in the decision-making for globe-preserving therapy in this context.

Methods: Observational retrospective case series. Included were retinoblastoma patients who presented at least one cloud seeding during their follow-up. Patients were examined on a monthly basis under general anesthesia with indirect ophthalmoscopy, Retcam photography, dynamic B-scan ultrasonography. MRT was performed at diagnosis and repeated in specific cases. Treatments included intravenous and/or intra-arterial chemotherapy as well as intravitreal chemotherapy. Additional focal treatments were given as needed.

Results: Cloud seeding can be present at diagnosis or can occur as a secondary event during the course of conservative treatment. Most frequently clouds appear as dense intravitreal avascular tumor mass resulting from the translocation of tumor content into the vitreous after disruption of the internal limiting membrane/posterior hyaloid. However, a double or even a triple-cloud can be seen in the same eye, if the tumor spreads concomitantly in the retrohyaloidal space (secondary to a rupture of the internal limiting membrane under a detached posterior hyaloid) and/or the subretinal space (secondary to a rupture at the tumor base under a detached retina). On B-ultrasonography, retrohyaloidal clouds are characterized by a position-dependent circular level obscuring the optic nerve head, whereas subretinal clouds preserve the visibility of the papilla. Complete response was obtained for subretinal clouds with intravenous or intraarterial chemotherapy, while intravitreal and retrohyaloidal clouds responded to additional intravitreal injection of melphalan.

Conclusion: Simple, double or triple clouds can occur in the same retinoblastoma eye and be treated conservatively with vision preservation. Dynamic ultrasonography is critical to determine tumor localization and assess for optic nerve involvement in this context.

FP 8

Apraclonidine in diagnosis of Partial Horner Syndrome in children

Amit Chhabra, Daniel Jackson, Darius Hildebrand
Oxford University Hospital NHS Trust, Oxford,
United Kingdom

Speaker: Amit Chhabra

Introduction: Apraclonidine hydrochloride is an α -adrenergic receptor agonist with strong α_2 and weak α_1 activity. It has at least the same sensitivity and specificity as cocaine in the diagnosis of Horner Syndrome (HS) in adults. Its availability is much easier than the other drugs recommended for pharmacological testing in HS - cocaine and hydroxyamphetamine. Although it has been used safely for perioperative intraocular pressure lowering in paediatric glaucoma surgery, its use in pharmacological testing for HS in children has been hindered by few adverse effects reported in infants. We sought to determine adverse effects of Apraclonidine eye drop instillation for diagnosis of Horner Syndrome in children at a referral centre.

Methods: A retrospective case review of the eye notes, clinic letters and radiology reports for all children presenting with anisocoria who underwent Apraclonidine diagnostic testing in the Paediatric Ophthalmology Service at the Oxford Eye Hospital in the United Kingdom between 2015-2018. A single drop of Apraclonidine (Iopidine; Alcon Laboratories UK Ltd) 0.5% was instilled in both eyes of all infants and two older children aged 2 and 2.5 years. Other children received a concentration of 1%. Parents were instructed to perform punctal occlusion for 1 minute after drop instillation. All children were observed for 2 hours after testing.

Results: We identified 19 children (10 boys and 9 girls) with significant anisocoria (1mm or more) in an age range of 3 months to 17 years (mean 6.1 years). 3 infants were present in this group. Of these, only 2 had ptosis (ie full HS) and were pharmacologically confirmed. The other 17 were anisocoria without ptosis, of whom 6 (35%) had a positive pharmacological response with equalisation or reversal of anisocoria suggesting a diagnosis of partial HS. 16% (1/6) of the children with partial HS were found to have intracranial pathology (Schwannoma/NF2) on neuro-imaging. Testing was well tolerated in all children without any side-effects.

Conclusion: There was a high incidence of partial Horner Syndrome in our study and pharmacological testing was valuable in its diagnosis. We recommend of pharmacological testing with Apraclonidine in children with significant anisocoria, especially those without ptosis, followed by neuroimaging for any residual clinical concern. We advise punctal occlusion for 1 min and clinical observation for 2 hours in a hospital setting with access to acute paediatric care.



Free Paper Abstracts

FP 9

Treatment of Retinopathy of Prematurity in the Netherlands between 2010-2016

Kasia Trzcionkowska¹, Wouter Vehmeijer¹,
Frank Kerkhoff², Jacqueline Termote³,
Nicoline Schalijs-Delfos¹

¹ Leiden University Medical Center, Netherlands

² Maxima Medical Center, Veldhoven, Netherlands

³ Wilhelmina Childrens Hospital, Utrecht, Netherlands

Speaker: Kasia Trzcionkowska

Introduction: For several years the impression amongst pediatric ophthalmologists in the Netherlands arose that the overall severity of Retinopathy of Prematurity (ROP) increases and that more infants require ROP-treatment. Within this period, crucial changes were conducted in premature care. While a lower age in which active resuscitation and neonatal intensive care are offered (2010) and higher administered oxygen levels (2014) increase the risk for ROP, the Dutch ROP-guideline (April 2013) emphasized the early treatment of ROP-criteria (ETROP) implying more infants will require ophthalmic intervention. The aim of the present study was to investigate the influence of these changes on ROP-treatment in the Netherlands.

Methods: Retrospective inventory on anonymized data of ROP-treatments between 2010-2016.

Results: Overall 196 infants were included and categorized into group A(A): 57 infants (113 eyes), treated between 1-1-2010 and 31-3-2013, and group B(B): 139 (275 eyes), from 1-4-2014 to 31-12-2016. After correcting for the inclusion-period a 2.1-fold increase in ROP-treatments was found. Overall mean gestational age (GA) at birth and birth weight (BW) were 25.9 (± 1.7) and 772 (± 240) grams respectively. The groups were comparable regarding GA (A: 25.9 (± 1.7) weeks, B: 26.0 (± 1.7) weeks, $p=0.711$) and BW (A: 715 (± 184), B 730 (± 205) grams, $p=0.967$). The prevalence of neonatal risk factors associated with ROP was comparable. At treatment decision, ROP-stage 3 was found in 58.8% in A vs. 61.1% in B ($p=0.680$). Laser photocoagulation was the predominant modality of primary treatment (97%), six infants received intravitreal Bevacizumab. In 31 infants ROP recurred and was retreated (A:10, B:21, $p=0.160$), varying from 10.0-37.5% within the hospitals. In 19 infants ROP progressed to retinal detachment (A:6, B:13, $p=0.791$) of which 8 bilateral (A:2 and B:6, $p=0.599$), with a spread of 3.4-25.0% amongst the participating clinics.

Conclusion: The number of infants requiring ROP treatment has more than doubled during the seven-year study period for which a declining age, a more aggressive oxygen regime and earlier treatment are suspected to be responsible. Earlier treatment however should not imply an equal increase in retinal detachment. Together with the similar number of high stages at treatment in both groups, insufficient implementation of the ETROP-criteria can be suggested.

FP 10

Visual cognitive problems captured with a structured history inventory in extremely preterm born children aged 6.5 years

Kerstin Hellgren¹, Mariagrazia Benassi²,
Melissa Libertus³, Jenny Bolk¹, Ulrika Ådén¹,
Lena Jacobson¹

¹ Karolinska Institutet, Stockholm Sweden

² University of Bologna, Bologna, Italy

³ University of Pittsburgh, Pittsburgh, PA, United States

Speaker: Kerstin Hellgren

Introduction: Cognitive and visual deficits have frequently been reported in preterm born populations. A question inventory has previously been found useful in identifying children with perceptual and cognitive visual problems. The purpose was to evaluate cognitive visual deficits in extremely preterm children (EPT, <27 weeks) compared to full-term peers at 6.5 years.

Methods: A population-based cohort of all surviving EPT children (n=120) born in the Stockholm area between January 1st, 2004 and March 31st, 2007 was assessed and compared with a term-born control group, as part of a prospective national follow-up study (EXPRESS). Assessments were made of ophthalmological outcome, IQ, motion and form perception, number sense acuity, as well as visual-motor integration. A structured history was taken by using a 39-question inventory to identify cognitive visual deficits. There were five possible levels of responses at each item and high scores indicated more problems.

Results: The 95 (of 120; 79%) participating EPT children had worse average scores on the questionnaire than the 95 (of 98; 97%) control children ($p<0.001$). In the EPT group, almost a third of the children (29%; n=28) exceeded the 90th percentile of the control group in 10 (26%) of the 39 questions. Those high scoring EPT children had significantly lower visual acuity ($p=0.001$), more strabismus (0.026), lower IQ ($p=0.008$) and worse results on motion ($p=0.012$), form ($p=0.032$) as well as visual-motor integration tasks ($p=0.013$).

Conclusion: The question inventory for structured history-taking seemed to be a useful tool in identifying EPT children with cognitive visual deficits.



FP 11

Visual function is reduced in formerly prematurely born young adults - a population-based study

Eva Larsson, Dyrleif Petursdottir, Gerd Holmström
Department of Ophthalmology, Uppsala University, Uppsala, Sweden

Speaker: Eva Larsson

Introduction: The aim was to assess the visual acuity (VA), visual field (VF) and contrast sensitivity (CS) in young adults born preterm, previously screened for retinopathy of prematurity (ROP) and followed up to 10 years of age, and to compare the results with individuals of the same age born full-term.

Methods: Individuals previously born preterm and screened prospectively for ROP and included in a 3.5- and 10-year population-based follow-up were included in the study. The preterm individuals were examined together with individuals of the same age, born in the same area and at term. Best-corrected VA was assessed both at distance and near with EDTRS charts (logMar). Visual acuity was also measured with Lea Hyvärinen (LH) charts as single symbols and in a row and crowding was calculated (single optotypes divided by optotypes in a row). Visual field was measured with Humphrey 24-2 and the mean deviation was noted. Contrast sensitivity was assessed with Vistech contrast sensitivity test and the area under the curve (AUC) was calculated.

Results: Fifty-nine preterm and 44 full-term individuals were included. All individuals were between 25-27 years at the time of examination. Preterm individuals had significantly lower distance VA (-0.08 vs -0.14 logMar, $p=0.004$), near VA (-0.08 vs -0.13 logMar, $p=0.007$), mean deviation (-1.05 vs -0.71 dB $p=0.03$) and CS (2.02 vs 2.16, $p<0.001$) compared to full-term individuals. Regarding VA and CS the differences were evident also after excluding persons with previous ROP and neurological complications. Regarding crowding no difference was found at this age.

Conclusion: Visual function including VA, VF and CS is reduced in prematurely born individuals also up in adulthood. Prematurity per se may cause the reduced visual functions, which were found also in individuals without previous ROP or neurological complications.

FP 12

Optical coherence tomography in the evaluation of children with neurofibromatosis type 1

Urszula Kulik¹, Maria Nilsson¹, Ulrika Sandvik¹, Klas Blomgren², Kerstin Hellgren¹

¹ Karolinska Institutet, Department of Clinical Neuroscience, Stockholm, Sweden

² Karolinska Institutet, Department of Women and Childrens Health, Stockholm, Sweden

Speaker: Urszula Kulik

Introduction: Children with neurofibromatosis 1 (NF1) have a predisposition for optic pathway gliomas (OPGs). They require regular ophthalmologic monitoring as they can experience visual acuity (VA) and/or visual field loss, typically progressing over a period of months to years. The purpose of this study was to evaluate optical coherence tomography (OCT) findings by quantifying the ganglion cell layer-inner plexiform layer (GCL-IPL) thickness in a group of children with NF1 with and without symptomatic OPG.

Methods: A population-based group of children with NF1 in the Stockholm area was enrolled in a prospective study. All of them underwent complete ophthalmic examination including best-corrected visual acuity (BCVA), visual field examination, neuro-ophthalmologic examination, fundus photography and OCT imaging using Zeiss Cirrus HD-OCT. Outcome measures in this paper were VA, ocular motor function and GCL-IPL thicknesses. Brain MRI was only performed if any symptoms of OPG were displayed.

Results: Fifty-eight children (22 females, 36 males) born between 2010 and 2014 were included in the study. Eleven subjects had known OPG and 47 subjects did not. The number of eyes where both VA and OCT was obtained at the same visit was 82 (87%) and 17 (81%) without and with OPG, respectively. Mean age at the time of first OCT was 5.5 ± 1.3 years (range 3.2-8.0) in the studied population. Mean BCVA was 0.7 ± 0.3 and 0.9 ± 0.2 respectively in the eyes with and without OPG. Mean GCL-IPL thickness of the eyes with OPG was $70.9 \pm 9.8 \mu\text{m}$ and of those without known OPG was $84.5 \pm 5.7 \mu\text{m}$. Average GCL-IPL thickness was significantly lower in the NF1 patients with known OPGs ($p<0.001$). Furthermore, significant correlation was found between GCL-IPL thickness and BCVA ($p<0.001$).

Conclusion: In this group of children with NF1, measurements of OCT were successfully obtained at a fairly young age, when treatment could improve visual development. The use of OCT to quantify damage to the visual pathways may enable earlier detection of OPGs in NF1 patients.



FP 13

Brushfield spots and Wölfflin nodules unveiled in dark irides using near-infrared light

Cameron F. Parsa¹, Lavinia Postolache²

¹ Quinze-Vingts National Eye Hospital, Sorbonne University, Paris, France

² Erasmus Hospital, Université Libre de Bruxelles, Belgium

Speaker: Cameron F. Parsa

Introduction: To determine if structures such as Wölfflin nodules, or Brushfield spots in Down syndrome, can be established in dark irides.

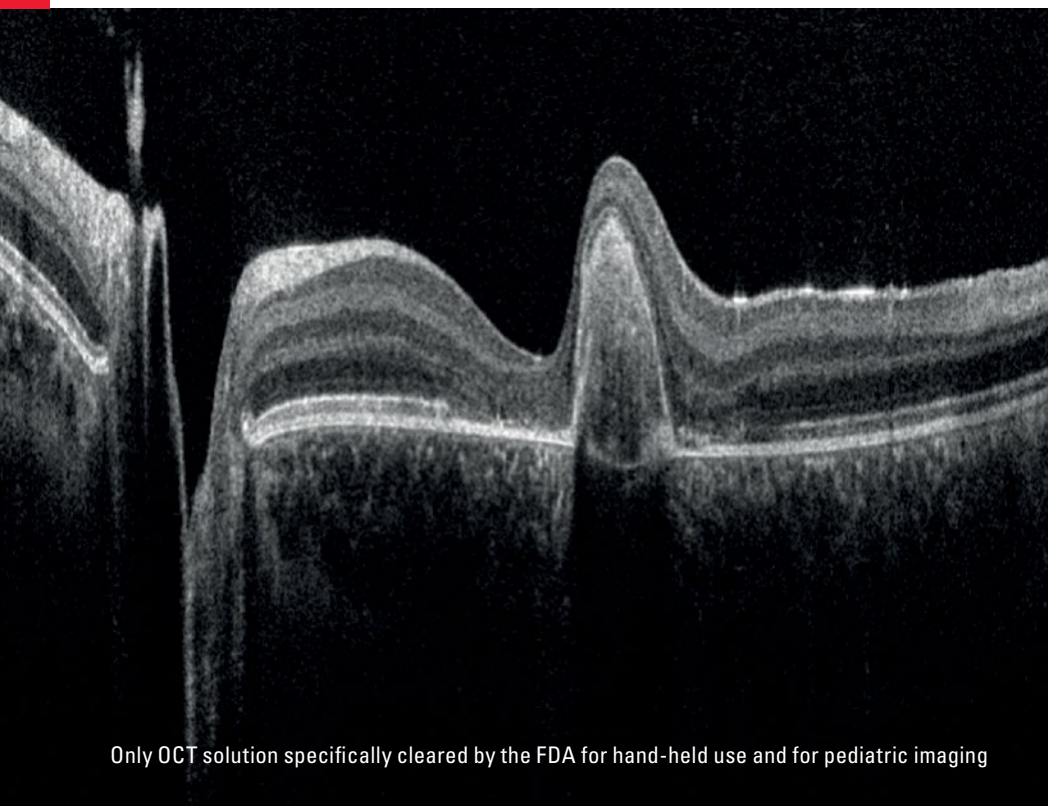
Methods: Iris photography of 43 children with, and of 43 control children without Down syndrome, were taken with standard visible white, as well as with near-infrared light. Main outcome measures: Identification of otherwise unseen iris features using near-infrared light in children with and without Down syndrome.

Results: Using white light, no child with darkly coloured irides had visible Brushfield spots or Wölfflin nodules. Brushfield spots were seen in 21% of children with Down syndrome, whereas smaller iris spots known as Wölfflin nodules were seen in 12% of controls ($p < 0.001$), all noted in those with lightly coloured irides. Using near-infrared light, Brushfield spots could, however, be seen in 58% of those with dark irides. Hence, using near-infrared light, Brushfield spots were detected overall in 67% of children with Down syndrome compared to 21% using white light alone ($p < 0.001$). Peripheral iris thinning was present in 62% of children with Down syndrome but in only 23% of those without ($p = 0.001$).

Contraction furrows were less frequent in children with Down syndrome (16%) compared to controls (74%) ($p < 0.001$).

Conclusion: Infrared light unveils the presence of Brushfield spots and Wölfflin nodules in dark irides, previously noted in lightly coloured irides alone. Clearing this discrepancy should assist in the elucidation of their pathophysiologic origin. A high prevalence of peripheral iris thinning is also present in children with Down syndrome along with a heretofore unreported reduction in iris contraction furrows.

From Eye to Insight



Only OCT solution specifically cleared by the FDA for hand-held use and for pediatric imaging



Easy on your Paediatric Patients

ENVISU HAND-HELD OCT FOR OPHTHALMOLOGY

Quickly capture and observe brilliant, high-resolution, and high-density optical coherence tomography (OCT) images with the Envisu C2300 hand-held OCT system.

- > Support diagnosis of pediatric ophthalmic pathology – brilliant, high resolution, deep-depth OCT imaging
- > Suitable for even premature infants – real-time, non-contact imaging for fast, gentle examinations
- > Take OCT to your patient – light-weight hand-held system for flexible use in the ICU, OR or clinic

Try Envisu live.
Join us on Saturday
and meet our expert
at the Leica booth

Contact your Leica expert

Didier Goor

+39.334.6400.692

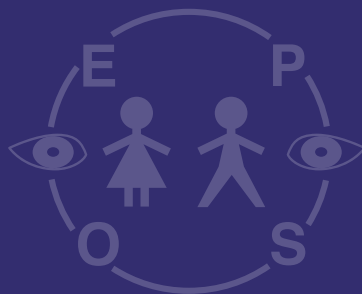
Didier.goor@leica-microsystems.com

Find out more about our ophthalmology solutions

www.leica-microsystems.com/applications/medical/ophthalmology/



Video Presentations





9th September 2018

V 1

- V 1 Krisztián Nagy (Hungary):**
Surgical treatment of rare facial clefts
– A Case Report
- V 2 Daniel Jackson (United Kingdom):**
Vitrector Pupilloplasty in young
children with small or ectopic pupils
- V 3 Miklós Resch (Hungary):** Pediatric
vitrectomy in crystalline lens dislocation

Surgical treatment of rare facial clefts – A Case Report

Krisztian Nagy, Zsuzsa Tallós

1st Department of Pediatrics, Semmelweis University,
Budapest, Hungary

Speaker: Dr. Krisztian Nagy

Introduction: Craniofacial clefts are very rare congenital anomalies, incidence varies between 1.43-4.85:100000. Every surgeon dealing with these malformations suggests to be inventive during the treatment. There are no standardised protocols, no large collected data exists. We are presenting 2 cases of Tessier 4 and 3 facial clefts respectively, 1st one a primary closure, the 2nd a reoperation.

Case 1: 11 m.o. boy referred to us as a newborn due to a right unilateral Tessier 4 facial cleft. Further investigation detected asymmetric lateral ventricles, ASDII, but no other major anomalies or chromosomal defect. After consulting with paediatric ophthalmologists we designed a joined approach by closing the soft tissue defect at a one stage repair. We used local rotational and transpositional skin flaps after closing the orbicularis oris muscle.

Case 2: 31 y.o. female with a Tessier 3 type facial cleft on the right, a cleft palate, and a hypoplasia of the maxilla, but no other congenital malformations. She had altogether 19 operations, and apart from the last 2, all were performed in other institutions. She was admitted to our hospital for the secondary correction of the nose and the facial scars. The right nostril was positioned upwards and everted, causing a visible facial asymmetry. We used a rotational flap from the midline of the nasal bridge to correct the deformity.

Conclusion: Even in large centres dealing with cleft surgery, craniofacial clefts are rare entities and therefore every case needs very accurate preoperative planning. In these cases we reached an aesthetically optimal result.



Video Presentations

V 2

Vitreor Pupilloplasty in young children with small or ectopic pupils

Daniel Jackson, Goran Darius Hildebrand
Oxford University Hospitals NHS Trust, Oxford,
United Kingdom

Speaker: Daniel Jackson

Introduction: Vitreor pupilloplasty allows pupil enlargement as part of managing the small pupil in paediatric cataract surgery or for the primary treatment of corectopia. Visual axis obscuration due to corectopia may lead to deprivational amblyopia and a small pupil during paediatric cataract surgery can present intraoperative challenges. The experience with vitreor pupilloplasty in very young children is limited. We report the outcomes of this technique in a variety of recent clinical situations.

Methods: We report a case series of 5 eyes of 4 children who underwent vitreor pupilloplasty with a 23g or 25g anterior vitreor at our institution. Intraoperative details and postoperative data as well as surgical video material were collected.

Results: Child 1: 6-week-old with bilateral tiny pupils and cataracts. Following vitreor pupilloplasty, cataract surgery was successfully carried out in both eyes.

Child 2: 16-month-old with extreme iris coloboma obscuring the visual axis. This child is undergoing occlusion therapy for amblyopia.

Child 3: 2-year-old with extreme left corectopia as part of suspected Axenfeld-Rieger syndrome. Best corrected visual acuity (BCVA) at 2 weeks post pupilloplasty was logMAR 0.400.

Child 4: 4-year-old post-penetrating injury underwent secondary retropupillary intraocular lens insertion and pupilloplasty following primary repair of corneal laceration, iris tear and lens aspiration. Post-operative BCVA was logMAR 0.100.

All children post procedure had sufficiently enlarged pupils clearing the visual axis. No hyphaema was seen post-operatively and no secondary glaucoma, cataract, photophobia or uveitis has occurred to date.

Conclusion: We report the successful use of vitreor pupilloplasty in a range of scenarios in children between 6 weeks and 4 years of age. We demonstrate its effectiveness and safety in the treatment of visual axis-obstructing corectopia. We also report the effective use of vitreor pupilloplasty in congenital cataract surgery complicated by tiny unresponsive pupils. Pupil ring expanders may not be suitable for small eyes, whilst iris hooks would result in further corneal wounds requiring suturing and increasing risk of complications. A vitreor pupilloplasty also creates a permanently large pupil allowing for easier refraction, fundal and media examination post-operatively without complications in this series. We advocate its use as a way of permanently managing very small or ectopic pupils.

V 3

Pediatric vitrectomy in crystalline lens dislocation

Miklós Resch, Mária Bausz, Erika Maka
Department of Ophthalmology, Semmelweis
University, Budapest, Hungary

Speaker: Miklós Resch

Introduction: Lens can be subluxated due to various reasons in childhood, such as microspherophakia, Marfan-syndrome, buphthalmos or trauma. Aim of our study to present video demonstrations of the different surgical techniques.

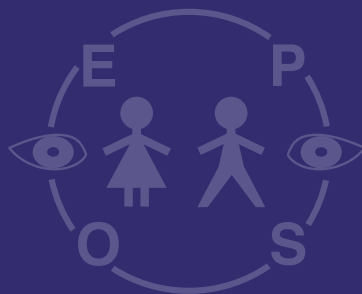
Methods: Retrospective analysis of surgical videos recordings from 2008-2018 related to vitrectomy in crystalline lens dislocation cases.

Results: Dislocated lens can be removed by pars plana and through clear corneal incisions as well depending on the location of the luxated lens. Vitrectorhexis can be performed with the 23G vitreous cutter and lensectomy or cortex removal could be completed with the help of this technique. Self healing wounds could be created, but in all cases closure with sutures is preferable.

Conclusion: Vitrectomy in pediatric lens dislocation is a safe and effective technique, which can be adapted to the individual situation and comorbidities with the prevention of risk for iatrogenic retinal disorders.



Rapid Fire + Poster Abstracts



Rapid Fire + Poster Abstracts



8th September 2018

- RF 1 Amit Chhabra (United Kingdom):** Low Incidence of Cerebral Venous Thrombosis in a 'Real World' Population of Paediatric Intracranial Tumours
- RF 2 Diogo Hipólito Fernandes (Portugal):** Large cup/disc ratio in Pediatric Age - SD-OCT and OCT-A evaluation
- RF 3 Diem Trang Nguyen (France):** The optic nerve in morning glory disk anomaly. An MRI study
- RF 4 Claudia Priglinger (Germany):** A retrospective analysis of Leber's Hereditary Optic Neuropathy (LHON) in childhood and treatment with idebenone
- RF 5 Zsuzsa Erdei (Hungary):** Clinical experience with idebenone treatment of adolescents with Leber's Hereditary Optic Neuropathy - 3 case reports
- RF 6 Alina Bakunowicz-Łazarczyk (Poland):** Selected antioxidant microelements serum concentration in myopic children and adolescents
- RF 7 Huda Al-Hayouti (United Kingdom):** Automated image quantification of conjunctival hyperaemia to measure activity of blepharokeratoconjunctivitis in children
- RF 8 Daniel Jackson (United Kingdom):** Outcomes of paediatric cataract surgery following Proton Beam Radiotherapy (PBRT) for Orbital Rhabdomyosarcoma (RMS)
- RF 9 João Leandro (Portugal):** The Adequacy of the Fogging Test in the Detection of Clinically Significant Hyperopia in School-Aged Children
- RF 10 Siobhan Ludden (United Kingdom):** Anterior segment OCT to evaluate the effectiveness of cycloplegia in children
- RF 11 Shalhevet. Goldfeather Ben Zaken (Israel):** Anterior segment OCT to evaluate the effectiveness of cycloplegia in children: Foveal hypoplasia as a cause for unexplained poor visual acuity
- RF 12 Jorge Meira (Portugalia):** Morphological evaluation of the macular retina in amblyopia
- RF 13 John E A Somner (United Kingdom):** Hermansky Pudlack Syndrome - why it takes more than a circumcision to make the diagnosis
- RF 14 Alenka Lavrič Groznik (Slovenia):** Clinical and anterior segment OCT features of conjunctival nevi in children
- RF 15 Gilles Martin (France):** Paramacular retinal atrophy and cerebral vasculopathy in homozygous sickle cell disease
- RF 40 Marie-Claire Gaillard (Switzerland):** Invisible Retinoblastoma: the role of OCT
- RF 16 Damien Yeo (United Kingdom):** Diagnostic difficulties in retinoblastoma: an analysis of pseudoretinoblastomas in a tertiary referral centre in the UK
- RF 17 Guenther Rudolph (Germany):** Familial exudative vitreo-retinopathy - FEVR. A diagnostic and treatment challenge



Rapid Fire + Poster Abstracts

9th September 2018

- RF 18 Evangelia Ntola (Sweden):** Ophthalmological findings in infants with non-syndromic craniosynostosis : a preliminary report
- RF 19 Sally Painter (United Kingdom):** Unilateral ptosis is rarely amblyogenic
- RF 20 Maria Samouilidou (Greece):** Congenital Nasolacrimal Duct Obstruction preferred practice patterns among EPOS members
- RF 21 Mervyn Thomas (United Kingdom):** Optic Nerve Head Abnormalities Associated with Congenital Fibrosis of Extraocular Muscles
- RF 22 Filipa Teixeira (Portugal):** Optic Disc Drusen in Children: Morphologic features using enhanced depth imaging optical coherence tomography
- RF 23 Aylin Taner (Switzerland):** Improved survival lead to higher ROP incidence in extremely preterm infants
- RF 24 Stella Moutzouri (Greece):** Retinopathy of prematurity: frequency and associated risk factors in a large Greek cohort
- RF 25 Anna Chmielarz-Czarnocińska (Poland):** The role of platelet count in the pathogenesis of retinopathy of prematurity
- RF 26 Dimitrios Kardaras (Greece):** The association between retinopathy of prematurity and ocular growth
- RF 27 Anna Chmielarz-Czarnocińska (Poland):** Results of treatment of retinopathy of prematurity in Poland, a single center analysis
- RF 28 Irina Trifanenkova (Russia):** Informativeness of optical coherence tomography-angiography in children with active stages of retinopathy of prematurity
- RF 29 Yaroslava Wenner (Germany):** Comparison of the optic nerve head parameters and RNFL in premature and full term children with OCT
- RF 30 Ana Ortueta-Olartecoechea (Spain):** Retinal ganglion cells complex in preterm children at childhood
- RF 31 Ana Ortueta-Olartecoechea (Spain):** Retinal ganglion cells complex and neonatal determinants: an optical coherence tomography study in very preterm children at school-age
- RF 32 Anita Csorba (Hungary):** Using in vivo confocal microscopy and anterior segment optical tomography in nephropathic cystinosis
- RF 33 Hajnalka Horvath (Hungary):** Comparison of quantitative measurement of foveal avascular zone and macular vessel density in eyes of children with chronic kidney disease and healthy controls
- RF 34 Eva Roomets (Estonia):** Wide-Field Autofluorescence Imaging for Follow-up of LCHAD Deficiency Chorioretinopathy
- RF 35 Bettina Tabori (Hungary):** Foveal avascular zone and macular vessel density in eye of healthy children
- RF 36 Dora Somodi (Hungary):** OCTA findings in patients with Stickler syndrome compared to normal population
- RF 37 Daniel Jackson (United Kingdom):** Diagnosing retinal laser injuries using near-infrared autofluorescence
- RF 38 Eleni Papageorgiou (Greece):** Multimodal retinal imaging in pediatric traumatic maculopathy
- RF 39 Malandain Edouard (France):** Macular OCT in Early-Onset Severe Retinal Dystrophies



RF 1

Low Incidence of Cerebral Venous Thrombosis in a 'Real World' Population of Paediatric Intracranial Tumours

Amit Chhabra, Guy Mole, Darius Hildebrand
Oxford University Hospital NHS Trust, Oxford, United Kingdom

Speaker: Amit Chhabra

Introduction: The incidence of cerebral sinus venous thrombosis is at least 0.67 per 100,000 children per year. Recent surgery and brain tumours have however been shown to be significant risk factors for the development of this condition. In addition cerebral sinus venous thrombosis is thought to be underreported although this has increased in recent years due to the greater prevalence of neuroimaging. The population of children with intracranial tumours seen at a neurosurgical center are therefore theoretically high risk for developing this condition due to the underlying pathology and treatments. In addition they undergo frequent clinic review and neuroimaging and so if they do develop a cerebral venous sinus thrombosis it is likely to be picked up. Our study aimed to determine the incidence of cerebral sinus venous thrombosis in children with intracranial tumours seen in the paediatric ophthalmology clinic at a referral center.

Methods: A retrospective case review of the eye notes, clinic letters, radiology and histology reports, and multi-disciplinary meeting outcomes for all children with an intra-cranial tumour who were seen in the Paediatric Ophthalmology Service at the Oxford Eye Hospital in the United Kingdom between 2012 and April 2017.

Results: We identified 129 children (82 boys [64%] and 47 girls [36%]) with intracranial tumours in our clinic who fulfilled the inclusion criteria. 13/129 (10.1%) had died (9 boys [70%] and 4 girls [30%]). The range of age at presentation was 0-17 years old (mean 5.8 years). We identified only one case of intracranial venous sinus thrombosis in the entire cohort and this was identified at the post-operative scan after tumour resection implying that surgery was the likely causative factor.

Conclusion: Tumours are generally pro-thrombotic and surgical interventions have been shown to increase the risk of cerebral sinus venous thrombosis. Our study of a 'real world' population of children with intracranial tumours at a neurosurgical center shows that despite close monitoring this is a relatively rare problem to be encountered with less than 1% of children developing it over an approximately 5 year period.

RF 2

Large cup/disc ratio in Pediatric Age - SD-OCT and OCT-A evaluation

Diogo Hipólito Fernandes, Elisa Luis Maria, Moura-Coelho Nuno, Crisóstomo Sara, Brito Cristina, Toscano Alcina

Department of Ophthalmology - Lisbon Central Hospital Center, Lisbon, Portugal

Speaker: Diogo Hipólito Fernandes

Purpose: Analyse peripapillary retinal nerve fiber layer (ppRNFL) using SD-OCT, as well as vascular density (VD) of the peripapillary vascular network (PVN) - OCT-A, between children with an increased cup/disc (C/D) ratio and normal ratio.

Methods: Non-randomized cross-sectional study of a sample of 28 eyes with an increased C/D ratio (group 1) and 28 eyes with a normal ratio (group 2), age and gender matched. Patients were characterized for cycloplegic spherical equivalent (cSE), intraocular pressure (IOP), C/D ratio and were evaluated for ppRNFL, macular thickness and PCN using SD-OCT and OCT-A. VD was obtained by AngioTool software.

Results: There was a significant decrease in the overall thickness of ppRNFL ($p=0.006$), as well as on the upper temporal ($p=0.013$), upper nasal ($p<0.001$) and nasal ($p=0.013$) quadrants in group 1, compared to group 2. Macular thickness in the external upper and nasal sector was also decreased in group 1. Children in this group had a significantly lower VD of those in group 2 ($p<0.001$). Unlike cSE ($p=0.003$), a significant difference in IOP between the two groups was not seen ($p=0.315$).

Conclusion: The observed differences make us question if optical discs with an increased C/D ratio are really healthy and show the significance of using OCT and OCT-A as screening methods in these children. Vascular density changes although potentially relevant, requires greater validation in order to guarantee reproducibility.



Rapid Fire + Poster Abstracts

RF 3

The optic nerve in morning glory disk anomaly. An MRI study

Diem Trang Nguyen, Nathalie Boddaert, Dominique Bremond Gignac, Matthieu Robert

Necker Hospital, Paris, France

Speaker: Nguyen Diem Trang

Introduction: The morning glory disk anomaly (MGDA) is a rare congenital malformation of the optic disk. The association with a significant enlargement of the optic nerve has been recently reported in few case reports, raising the question of potentially associated optic pathway gliomas. The aim of this study is to systematically evaluate the optic nerves of patients with confirmed MGDA, on magnetic resonance imaging (MRI) performed in order to rule out vascular progressing abnormalities.

Methods: Cerebral and orbital MRI of patients with confirmed MGDA seen in a single-centre between 2008 and 2018 were systematically reviewed. Anatomy of the optic nerve from the optic disk to the chiasm was evaluated.

Results: Eleven patients were included. All presented unilateral MGDA. Age at MGDA diagnosis was: 6-36 months, mean=14 months; age at first MRI was: 0.5-61 years, mean=9 years). MRI showed staphyloma centered by the optic disk in 10 cases (91%) and ipsilateral optic nerve anomalies in 9 cases (82%). The optic nerve was found thinner than the contralateral one in its intraorbital, intracanal and intracranial portions in one case (9%). In eight cases (73%), the thickness of the optic nerve was irregular and varied along its pathway: thick, normal or thin. None of these cases exhibited gadolinium enhancement. When serial MRI scanning was available (5 cases), there was no evolution of the anomaly.

Conclusion: In patients with MGDA, optic nerve and chiasm abnormalities are the rule, with most often unique pattern of irregular optic nerve thickness, from the orbit to the chiasm. Such pattern should be recognised and points to a developmental abnormality, rather than an optic nerve glioma.

RF 4

A retrospective analysis of Leber's Hereditary Optic Neuropathy (LHON) in childhood and treatment with idebenone

Claudia Priglinger¹, Felice Lob¹, Claudia Catarino², Bettina von Livonius¹, Thomas Klopstock², Günther Rudolph¹

¹ Department of Ophthalmology, Ludwig-Maximilian University of Munich, Munich, Germany

² Friedrich-Baur Institute, Department of Neurology, Ludwig-Maximilian University of Munich, Munich, Germany

Speaker: Claudia Priglinger

Introduction: Leber's Hereditary Optic Neuropathy (LHON) is a maternally inherited disease caused by mitochondrial DNA mutations, which is generally recognized as a disease of young adults between 15-35 years of age. Here we describe the clinical and molecular characteristics of patients with disease onset before the age of 16 years (early onset LHON) and monitor their visual acuity in the course of treatment with idebenone.

Methods: Out of 418 LHON patients in our database, 277 were analysed regarding gender, age at onset before the age of 16 years, genetic mutation and visual acuity. Mann-Whitney-U -Test was used for statistical Analysis.

Results: We identified 32 patients with an age of onset between 4 and 16 years. The overall proportion of early-onset disease was higher in male than in female patients (81,1% vs. 18,8%). Remarkably, in patients with an age of onset before or at thirteen (n=17), 70.5% were male and 29,4% female, while all patients affected between 14 and 16 years (n=15) were male with 6 being smokers. The mtDNA mutations m.11778G>A and m.3460G>A were found 53,1%, 15,6%, 21,9%, respectively, and 9,4% had rare mutations. All patients were treated with idebenone. Mean bilateral visual acuity was 1.05 LogMAR before treatment and 0.85 LogMAR after 12 months. No severe side effects were reported.

Conclusion: LHON should be considered in the differential diagnosis of subacute blindness in younger patients. The high abundance of males in the early onset age group between 14 and 16 years suggests protective factors in females upon reaching puberty. Idebenone is safe in Children between 4 and 16 years of age.



RF 5

Clinical experience with idebenone treatment of adolescents with Leber's Hereditary Optic Neuropathy - 3 case reports

Zsuzsa Erdei¹, Otto Alexander Maneschg²,
Viktória Szabó², Zoltán Nagy Zsolt²,
Krisztina Knézy²

¹ St. John Hospital, Department of Ophthalmology

² Semmelweis University, Department of Ophthalmology

Speaker: Zsuzsa Erdei

Introduction: Leber's hereditary optic neuropathy (LHON) is a bilateral progressive optic neuropathy of mitochondrial inheritance. LHON mutations cause mitochondrial disruption of the oxidative phosphorylation. The majority of patients with LHON have one of the three primary mtDNA point mutations: 3460G>A in MT-ND1, 14484T>C in MT-ND6, 11778G>A in MT-ND4 genes.

Idebenone is a short-chain benzoquinone, a potent antioxidant, it overcomes mitochondrial complex I respiratory chain deficiency in patients with LHON by transferring electrons directly to mitochondrial complex III.

Patients and methods: We report the clinical findings of 3 patients from pediatric age group (1 female, 2 males) with acute onset of visual loss due to LHON. The age ranged from 10.5 - 17 years. Molecular genetic analysis showed mutations in one case at 3460G>A and in two cases at 11778G>A position. The time from diagnosis to the beginning of the therapy was 11 months on average. All patients were treated with oral idebenone 900 mg/day for 12 months. We examined the best corrected visual acuity (BCVA) monthly on ETDRS visual charts, furthermore we performed Goldmann perimetry in 3 months intervals. Optical coherence tomography (macula and optic nerve head) was taken at baseline and after 1 year.

Results: At baseline mean BCVA was 0.02-0.06 in decimals, Goldmann perimetry showed large central scotomata. We noted a clinically relevant and stable improvement of BCVA of 10-49 letters on ETDRS charts in all patients, and central scotomata decreased significantly in all of them. We did not find any adverse effects during idebenone treatment.

Conclusions: Treatment with idebenone was effective in young patients with Leber's optic neuropathy and well tolerated. All patients had an improvement of visual acuity and visual field - thus quality of life.

Keywords: LHON, Low vision, Idebenone, Optic Neuropathy

RF 6

Selected antioxidant microelements serum concentration in myopic children and adolescents

Alina Bakunowicz-Łazarczyk¹, Beata Urban¹,
Monika Fedor², Katarzyna Socha³,
Jolanta Soroczyńska³, Maria Borawska³

¹ Medical University of Białystok, Białystok, Poland

² Białystok University Childrens Hospital, Białystok, Poland

³ Department of Bromatology, Medical University of Białystok, Białystok, Poland

Speaker: Alina Bakunowicz-Łazarczyk

Introduction: There are some reports concerning the abnormalities in the Zn, Cu, Se and Mn metabolism in myopia, however, there are very few publications concerning the analysis of the serum content of the trace elements in myopic children, besides study results are sometimes inconsistent. The purpose of the present study was the assessment of the serum concentration of antioxidant microelements - Zn, Cu, Se, Mn and Cu/Zn ratio in children and adolescents with myopia.

Methods: 83 children were examined (mean age 14.36 ± 2.49 years) with myopia. The control group was 38 persons (mean age 12.89 ± 3.84 years). Each patient had complete eye examination. The serum concentration of zinc, copper, manganese and selenium was determined by atomic absorption spectrometry. Cu/Zn ratio, which is the indicator of the oxidative stress, was also calculated.

Results: The average serum concentration of zinc in myopic patients was significantly lower (0.865 ± 0.221 mg L⁻¹) in comparison to the control group (1.054 ± 0.174 mg L⁻¹). There was significantly higher Cu/Zn ratio in myopic patients (1.196 ± 0.452) in comparison to the control group (0.992 ± 0.203). The average serum concentration of selenium in the study group was significantly lower (40.23 ± 12.07 µg L⁻¹) compared with the control group (46.00 ± 12.25 µg L⁻¹). There were no essential differences between serum concentration of copper and manganese in the study group and the control group.

Conclusion: Low serum concentration of zinc and selenium in myopic children may imply an association between insufficiency of these antioxidant microelements and the development of the myopia and could be the indication for zinc and selenium supplementation in the prevention of myopia. Significantly higher Cu/Zn ratio in the study group can suggest the relationship between myopia and oxidative stress.



Rapid Fire + Poster Abstracts

RF 7

Automated image quantification of conjunctival hyperaemia to measure activity of blepharokeratoconjunctivitis in children

Huda Al-Hayouti¹, Mortiz Daniel¹, Melanie Hingoranie², Virginia Calder³, Annegret Dahlmann-Noor¹

¹ NIHR Moorfields Biomedical Research Centre at Moorfields Eye Hosp | ² Paediatric Service, Moorfields Eye Hospital, 162 City Road, London

³ UCL Institute of Ophthalmology, 11-43 Bath Street, London EC

Speaker: Huda Al-Hayouti

Introduction: The assessment of blepharokeratoconjunctivitis (BKC) severity involves an assessment of disease activity and damage to ocular structures. Grading scales inform management decisions, and are also used to evaluate responses to treatment in clinical trials, but are subjective.

The aim of this study was to compare automated measurements of ocular surface redness in children with BKC and in healthy volunteers (HV) and to test their agreement with a clinical activity scale (CAS).

Methods: This was a prospective observational case-control study of 31 children with BKC (median (interquartile range, IQR) 10.6 (7.2-13.9) years and 32 HV 11.4 (9.5-13.8) years attending Moorfields Eye Hospital. One eye of each participant was included in the study: the more severely affected eye in children with BKC, and the right eye in HV. Children underwent Oculus Keratograph 5M (Oculus, Wetzlar, Germany) colour photography with and without instillation of topical fluorescein. The images were reviewed by two masked observers to determine a clinical grading of BKC activity from 0-3. From the R-scan Keratograph images, the redness index (RI) for bulbar and limbal conjunctiva was noted, ranging from 0-4 in increments of 0.1 units.

Results: For observer 1, the median (IQR) clinical score for children with BKC was 1 (0-1) and for those without eye surface inflammation, the median was 0 (0-1). The difference was statistically significant ($p=0.043$). For observer 2, the median (IQR) for the BKC group was 1 (0-2), and for the healthy volunteer group it was 0 (0-0). The difference was statistically significant ($p<0.001$). Agreement of scores by the two observers was high (Cohen's Kappa 0.421, $p<0.001$). In children with BKC the median (IQR) bulbar and limbal RI was 1.3 (0.8-1.6) and 0.7 (0.3-1.1) respectively. In HV the median bulbar and limbal RI was 0.8 (0.55-1.1) and 0.3 (0.2-0.4) respectively. The difference between the group medians of limbal, but not bulbar RI was statistically significant (limbal: $p=0.02$). Agreement of CAS of observer 1 and Keratograph bulbar RI was high (Kendall's tau 0.551, $p<0.001$), as was agreement between CAS of observer 1 and Keratograph limbal RI (Kendall's tau 0.549, $p<0.001$). Agreement between CAS of observer 2 and bulbar and limbal RI was similar.

Conclusion: The Oculus Keratograph R-scan imaging allows reliable and objective grading of conjunctival redness which is an indicator of ocular surface inflammation activity.

RF 8

Outcomes of paediatric cataract surgery following Proton Beam Radiotherapy (PBRT) for Orbital Rhabdomyosarcoma (RMS)

Daniel Jackson, Jonathan H Norris, Goran Darius Hildebrand

Oxford Eye Hospital, Oxford University Hospitals, Oxford, United Kingdom

Speaker: Daniel Jackson

Introduction: RMS is the most common paediatric soft tissue sarcoma and has an excellent prognosis with a survival rate of greater than 85%. PBRT is increasingly used to treat patients with orbital RMS, theoretically sparing normal tissues with fewer side-effects than conventional radiotherapy. Visually threatening complications from PBRT have been reported, including cataract. There is a lack of data on management of paediatric cataract and outcomes of paediatric cataract surgery following orbital PBRT. We report our experience and outcomes of cataract surgery in children treated with PBRT for orbital RMS.

Methods: Retrospective case series of all children seen at a single paediatric tertiary referral centre (Oxford University Hospitals NHS Foundation Trust, UK) with a diagnosis of orbital RMS and who received PBRT. Preoperative and intraoperative details, complications and visual outcomes were extracted from medical records for the period between September 2010 and February 2018.

Results: Four patients received PBRT for orbital RMS, median age diagnosis 6 years (0.5-7 years). Median follow-up period was 3.5 years (1-7 years). Three required cataract surgery, median interval post-PBRT 2.5 years (2-2.5 years). Primary intraocular lens insertion was performed in all cases: two in the bag and one in the ciliary sulcus. Two developed posterior capsular opacification at 8 and 10 months, successfully treated with YAG capsulotomy. Longterm visual acuity for two patients was logMAR 0.00 and 0.325. The third case just commenced occlusion therapy post-surgery for amblyopia. Management was effected by pre-existing ocular surface disease. No patients developed secondary glaucoma, retinopathy or neuropathy to date.

Conclusions: We report the first case series detailing technical aspects and outcomes of cataract surgery in children post PBRT for orbital RMS. Cataract was a common complication in our cohort, with 75% requiring surgery at a median interval of 2.5 years post PBRT. There are significant challenges associated with paediatric cataract surgery, particularly in post-radiation eyes. Technical challenges arise from compromised ocular surfaces and fragile capsules. Careful management can still result in rewarding outcomes, as we demonstrate. Larger and longer-term data are required on the management of cataract in these patients and visual outcomes as PBRT becomes more available.



RF 9

The Adequacy of the Fogging Test in the Detection of Clinically Significant Hyperopia in School-Aged Children

João Leandro, Carla Sofia Ferreira, Renato Santos-Silva, Augusto Magalhães, Jorge Breda, Fernando Falcão-Reis
Hospital São João, Porto, Portugal

Speaker: Jorge Meira

Purpose: To evaluate the efficacy of the “fogging test”, performed with a +2 diopters (D) lens, in the detection of clinically significant hyperopia in school-aged children.

Methods: We studied 54 children between 5 and 11 years of age, with 10/10 best corrected bilateral visual acuity (VA) without significant degree of correction. VA was assessed in each eye with a “bilateral” +2D sphere over-refraction followed by cycloplegic retinoscopy. The capacity of the test to detect hyperopia of $\geq +2D$ and $\geq +1.5D$ was evaluated by examining the respective receiver operating characteristic (ROC) curves and sensitivity and specificity values for different cutoff values of VA.

Results: For the detection of hyperopia $\geq +2D$, the area under the ROC curve (AUC) was 0.955 ($p \leq 0.001$). The VA cut-off with best discriminative capacity was $\geq 5/10$, with a sensitivity of 100%, specificity of 79%, positive predictive value (PPV) of 57% and negative predictive value (NPV) of 100%. In respect to $\geq +1.5D$ hyperopia, the test capacity was lower (AUC=0.832; $p \leq 0.001$). The best VA cutoff was also of $\geq 5/10$, with a PPV of 81% and a NPV of 85%.

Conclusion: The accuracy of the test was high for the evaluation of $\geq +2D$ hyperopia but lower for $\geq +1.5D$ hyperopia. For the detection of $\geq +2D$ hyperopia, the VA cutoff of $< 5/10$ may permit the exclusion of clinically significant hyperopia in selected children, without the need for cycloplegia. For the same cutoff, the PPV was low, meaning that in children with $\geq 5/10$ VA cycloplegic refraction remains obligatory.

RF 10

Anterior segment OCT to evaluate the effectiveness of cycloplegia in children

Siobhan Ludden, Huda Al-Hayouti, Annegret Dahlmann-Noor
NIHR BRC at Moorfields and UCL Institute of Ophthalmology, London, United Kingdom

Speaker: Siobhan Ludden

Introduction: Cycloplegic retinoscopy is the gold standard for identifying refractive error in children. At Moorfields Eye Hospital, London, the cycloplegia protocol advises one application of cyclopentolate (CP) 1% in light irides and two applications of CP 1% and phenylephrine (PE) 2.5% in dark irides. However, PE is a mydriatic and published evidence has questioned the effect of PE on accommodation. The aim of this study was to evaluate the efficacy of this PGD in blue/green (BG), light brown (LB) and dark brown (DB) irides as part of an ongoing quality improvement project.

Methods: We assessed one eye of 67 healthy children, mean (SD) 6 (1.2) years, attending for cycloplegic refraction at Moorfields' paediatric outpatient clinics. Anterior segment OCT (AS-OCT, Tomey Casia2) was used to objectively evaluate cycloplegia. We obtained an AS-OCT to an accommodative target at 0D and 6D accommodative demand before and 30 minutes after the instillation of cycloplegic eye drops. We acquired automated measurements of participants' pupil size, the radius of curvature of the front (RCFront) and back lens surface (RCBack), lens thickness (LT) and lens diameter (LD) before and after cycloplegia.

Results: We assessed 20 BG, 16 LB, 27 DB and 4 atropinised eyes. Before eye drop instillation, mean pupil size decreased on accommodation in all iris groups. After cycloplegia, accommodation no longer induced reduction in pupil size in either group. Accommodative effort induced a significant increase in LT prior to cycloplegia, from mean (\pm SD) 3.7 (0.2) to 3.8 (0.2) mm ($p < 0.001$). Cycloplegia lead to reduction in LT to 3.5 (0.2) mm, and no reaction to accommodative effort ($p = 0.567$).

RCFront mean (\pm SD) decreased from 9.9 (1.5) to 8.9 (1.4) mm with accommodation ($p < 0.001$); cycloplegia increased RCFront to 11.8 (1.6) mm, no decrease occurred with accommodation.

There was no significant difference in LD and RCBack with accommodative effort, before or after eye drops.

Conclusions: AS-OCT can be used to objectively demonstrate effective cycloplegia. Adequate cycloplegia can be achieved in BG eyes with a single drop of CP 1%. One drop of CP 1% and PE 2.5% results in adequate cycloplegia in LB and DB irides. Further research is required to evaluate if pupil dilation achieved with CP 1% alone is sufficient for accurate retinoscopy in LB and DB irides.



Rapid Fire + Poster Abstracts

RF 11

Foveal hypoplasia as a cause for unexplained poor visual acuity

Shalhevet. Goldfeather Ben Zaken, Hana Leiba, Beatrix Hadas, Niv Levi, Peter Hoffman, Reut Parness-Yossifon

Kaplan Medical Center, Rehovot, Israel

Speaker: Leiba Hana

Introduction: Different grades of foveal hypoplasia, defined as an undeveloped fovea, are often described in associations with other ocular disorder, such as infantile nystagmus, and albinism, but can also be seen as an isolated entity. Recent studies have shown that OCT can be used as a diagnostic and prognostic tool in foveal hypoplasia.

The purpose of this study is to present six children that were sent for evaluation due to unexplained suboptimal BCVA, with neither gross ocular or systemic findings, which could explain their poor BCVA. In all, some various degree of foveal hypoplasia was found in OCT examination.

Methods: Full ophthalmic examination including BCVA, manifest refraction, the presence of nystagmus, strabismus, stereo acuity, anterior segment, retinal findings and spectral domain optical coherence tomography were performed in all children, and whenever possible on first degree relatives.

Results: Children's age ranged from 6 to 13.5, 2 males and 4 females. Visual acuity ranged from 6/7.5 (0.1 Logmar) to 6/18 (0.20 Log mar). All children had some degree of foveal hypoplasia according to the OCT grading system.

On evaluation of family members, foveal hypoplasia was found in 2 (33.3%) families. Further evaluation revealed albinism in one family.

Conclusion: OCT of the macula may reveal pathology that cannot be seen in ophthalmoscopy, especially in young children. Macular hypoplasia revealed by OCT can be isolated but can also lead to further investigation, and may be the first sign of a familial syndrome such as albinism.

RF 12

Morphological evaluation of the macular retina in amblyopia

Jorge Meira¹, Diana Ramos-Rocha², Paulo Freitas-Costa¹, Jorge Breda¹, Fernando Falcão-Reis¹

¹Department of Ophthalmology, Centro Hospitalar de São João, Porto, Portugal

² Faculty of Medicine, Porto University, Porto; Portugal

Speaker: Jorge Meira

Introduction: Amblyopia is the most common cause of visual impairment in children and persists often in adulthood. The introduction of optical coherence tomography (OCT) in clinical practice allowed a precise evaluation of the human's eye macular retina morphology, opening a new window to study its structure in patients with amblyopia.

Methods: Systematic review of original articles indexed in PubMed / MEDLINE, in which the foveal macular thickness was evaluated in patients with amblyopia, published between 2005 and 2018. A total of 28 articles were found; seven were excluded.

Results: All studies were cross-sectional in nature. Nineteen studies used the fellow eye of the patient with amblyopia as a control and five studies used a group of individuals without amblyopia. Six studies used time-domain and fourteen studies a spectral-domain OCT. A significant increase of the central macular thickness (foveal, 1mm) in the amblyopic eye was reported in 8/21 studies.

Conclusion: The results suggest that amblyopia can be interpreted as a pathology with structural changes not only in the central nervous system, but also in the eye, particularly in the retina. The fact that most of studies was cross-sectional, included a small number of patients and used different types of OCT makes the comparison of results difficult and sometimes contradictory. More studies, preferably prospective and with a larger sample size, will be required in the future.



RF 13

Hermansky Pudlack Syndrome – why it takes more than a circumcision to make the diagnosis

John E A Somner, Alki Liasis, Dorothy Thompson, Isabelle Russell-Eggitt, Ian C Lloyd
Great Ormond Street Hospital, London, United Kingdom

Speaker: John Somner

Introduction: Oculocutaneous albinism (OCA) is a well-known feature of the autosomal recessive Hermansky Pudlak Syndrome (HPS) which also features a bleeding diathesis and accumulation of ceroid lipofuscin. How the diagnosis of HPS is reached in cases of OCA is not yet standardised.

Methods: We review 5 cases of HPS which presented initially via the paediatric ophthalmology department and discuss the clinical features and diagnostic pathway.

Results: Four of the five patients were born to consanguineous parents. Nystagmus was noted in 3 of 5 patients. Visual acuity was reduced in all patients and varied from 0.3 to 1.05 LogMAR. All patients had astigmatism. Electrodiagnostic tests confirmed fibre misrouting at the chiasm of the type associated with albinism in all cases and all the patients had foveal hypoplasia. One patient had chronic neutropaenia and another repeat bouts of tonsillitis. All had easy bruising or epistaxis from a young age but interestingly two had a history of early circumcision without excessive bleeding. Diagnosis was confirmed by genetic testing in two patients (HPS 2 and 3) and platelet function studies in three patients. All had normal platelet counts.

Conclusion: These cases highlight the importance of considering a history of bleeding or bruising when assessing patients with tyrosinase positive oculocutaneous albinism. The importance of making the diagnosis is highlighted as this can help patients and their families to deal effectively with any bleeding problems which may occur as a result of any planned surgery, dental work or due to the arrival of the menarche. The importance and feasibility of early genetic testing is discussed with particular regard to highlighting associations of variants of HPS with long term sequelae such as pulmonary fibrosis, granulomatous colitis, haemophagocytic lymphohistiocytosis and renal failure. With a genetic diagnosis patients and their families are better able to plan their care and to anticipate and manage known problems related to HPS.

RF 14

Clinical and anterior segment OCT features of conjunctival nevi in children

Alenka Lavrič Groznik, Špela Markelj, Manca Tekavčič Pompe
University Eye Clinic, Ljubljana, Slovenia

Speaker: Manca Tekavčič Pompe

Introduction: Melanocytic conjunctival nevus is the most common pediatric conjunctival tumor. Nevus usually becomes visible in the first to second decade. It can vary in colour, size, presence of intrinsic cysts and vascularity. Absence of feeder vessel and presence of intrinsic cysts is usually consistent with benign lesion. Malignant transformation is less than 1% and surgical removal is performed for cosmetic reasons or suspected malignancy. The aim of the study was to describe the anterior segment optical coherence tomography (AS-OCT) characteristics of conjunctival nevi in pediatric population at University Eye Clinic in Ljubljana.

Methods: Prospective interventional case series. Eighteen patients with conjunctival nevi were evaluated clinically, the nevi were imaged with AS-OCT. Nevus thickness, basal diameter, shape of the lesion, visibility of margins and presence or absence of posterior shadowing were evaluated. All lesions were excised due to cosmetic reasons. Histopathology results of excised lesions were collected.

Results: The mean patients age was 10.3 years (range 6-16). All lesions were optically solid. The mean nevus thickness was 0.47 ± 0.16 mm with mean basal diameter 3.94 ± 1.18 mm. Dome shaped configuration was noticed in 14/18 lesions (77.8 %). Nevus margins were seen in all patients. Posterior shadowing was present in 14/18 eyes (77.8 %). Histopathology confirmed compound nevus in 17/18 (94.4 %) and combined in 1/18 case (5.6 %). Intrinsic cysts were noticed clinically in 7/18 (38.9 %), using AS-OCT in 10/18 (55.5 %) and on histopathology examination in 9/18 (50 %) lesions. No malignant alteration was observed.

Conclusion: AS-OCT has shown its role in visualizing structure of the conjunctival nevi in children as well as in detecting intrinsic cysts. It can be used as a non-invasive tool which helps differentiate between different conjunctival lesions.



Rapid Fire + Poster Abstracts

RF 15

Paramacular retinal atrophy and cerebral vasculopathy in homozygous sickle cell disease

Gilles Martin¹, Valentine Brousse², David Grevent³, Dominique Bremond-Gignac¹, Pierre-Paul Vidal⁴, Matthieu Robert¹

¹ Ophthalmology Department - Necker University Hospital - APHP, Paris, France

² Paediatric Department - Necker University Hospital - APHP, Paris, France

³ Radiology Department - Necker University Hospital - APHP, Paris, France

⁴ COGNAC-G - Paris Descartes University - UMR 8257 - CNRS, Paris, France

Speaker: Gilles Martin

Introduction: Recent studies using OCT showed that atrophy of the median temporal raphe of the retina (ATR) was a frequent occurrence in sickle cell disease (SCD). However, the prevalence, natural history, mechanisms and significance of ATR is not known, especially in the paediatric field.

Methods: Homozygous (SS) SCD-children were prospectively included in two groups, according to their neurological status: children with no history of cerebral stroke and no abnormal transcranial Doppler (TCD) over their follow-up were included in group A, whereas children with a history of stroke or abnormal TCD were included in group B. All participants underwent a fundus examination and an OCT of the macula and the temporal retina, using specifically designed acquisition patterns on the Spectralis HRA+OCT (Heidelberg Engineering®, Germany). ATR was detected on thickness maps, as blue patches of thinned retina.

Results: Thirty-two children were included, 17 in group A and 15 in group B. The mean age was 13 (5,5-18) in group A and 11 (6-16) in group B. On the 32 children included, 69% exhibited ATR, while 22% had peripheral SCD retinopathy. ATR was found in 53% of children of group A vs 87% in group B (p=0.02).

Conclusion: ATR occurs early in children with SCD; it was found to be more frequent in children with a history of stroke and/or abnormal TCD. Further studies are needed to better characterise the pathophysiological and clinical meaning of this association.

RF 16

Diagnostic difficulties in retinoblastoma: an analysis of pseudoretinoblastomas in a tertiary referral centre in the UK

Damien Yeo, Charlotte Clifton, Maxine Fraser, Zishan Naeem, Mandeep Sagoo, M.Ashwin Reddy
Retinoblastoma Unit, Royal London Hospital, London, United Kingdom

Speaker: Damien Yeo

Introduction: Ruling out retinoblastoma can be difficult for the paediatric ophthalmologist as there are conditions that can mimic it. Our aim was to study the different types and frequency of pseudoretinoblastoma lesions.

Methods: Retrospective chart review of 517 patients referred to the Retinoblastoma Unit in the Royal London Hospital during a 9.5-year-period from Jan 2009 to June 2018. Patients with a known diagnosis or who were referred for screening were excluded.

Results: Out of the 324 patients included, 207 patients (64%) were confirmed to have retinoblastoma and 117 had pseudoretinoblastomas (36%). There were a total of 21 different pseudoretinoblastoma diagnoses. The top six most common conditions were: Coats' disease (37%), persistent fetal vasculature (16%), combined hamartoma of the retina and retinal pigment epithelium (13%), vitreoretinopathy (6%), astrocytic hamartoma (5%), toxoplasmosis (4%), and cataracts (4%). All Coats' patients were diagnosed with the use of fluorescein angiogram and ultrasonography.

Conclusion: A multitude of conditions can mimic retinoblastoma. Coats' disease is the most common pseudoretinoblastoma lesion. In our study, benign hamartomas appear to be a more common pseudoretinoblastoma lesion than previously reported. An early and accurate diagnosis is crucial in all patients as many cases will require further systemic workup.



RF 17

Familial exudative vitreo-retinopathy – FEVR. A diagnostic and treatment challenge

Günter Rudolph, Josef Michael Maertz, Armin Wolf, Claudia Priglinger, Oliver Ehrt, Siegfried Priglinger
Augenlinik der Ludwig-Maximilians Universität München, München, Germany

Speaker: Rudolph Günter

Hereditary exudative retinopathies represent clinically and genetically heterogeneous retinal disorders. The disease is characterized by incomplete development of retinal vascularisation due to incomplete angiogenesis. The underlying defect is associated with different genes affecting the Wnt-pathway, which is prerequisite to the normal formation of retinal vessels. Mutations in five different genes have so far been associated with familial exudative vitreoretinopathy. The frizzled receptor complex gene FDZ4, TSPAN 12, LRP5, the ligand Norrin-gene NDP and ZNF 408. The inheritance can be autosomal dominant in FZD4 and TSPAN 12 mutations, autosomal recessive in LRP5 and NDP mutations or X-linked.

The effect of the abnormal vascularisation results in ischemia of the peripheral retina leading to neovascularisation, exudation, haemorrhage, vitreoretinal traction and retinal detachment. The phenotype can range from mild vascular abnormalities up to complete retinal detachment and blindness.

Imaging of the retina is very helpful in making the diagnosis. In particular, OCT and wide-field fluorescein angiography are tools to identify the amount and the progression of the disease.

Treatment of hereditary exudative retinopathies can be a challenge. We here present two families with FDZ4 mutations who required cryo-coagulation, laser treatment, anti-VEGF injections or surgical procedures.

RF 18

Ophthalmological findings in infants with non-syndromic craniosynostosis: a preliminary report

Evangelia Ntoula¹, Daniel Nowinski², Gerd Holmström¹, Eva Larsson¹

¹ Dept. of Neuroscience, Uppsala University, Uppsala, Sweden

² Dept. of Surgical Science, Uppsala University, Uppsala, Sweden

Speaker: Evangelia Ntoula

Introduction: The aim was to report the ophthalmological findings in infants and children born with non-syndromic craniosynostosis preoperatively and 6-12 months after surgery

Methods: Infants referred to the Craniofacial Center, Uppsala University Hospital for surgery of craniosynostosis were examined. Patients with craniosynostosis syndromes were excluded. Preoperatively visual acuity was measured with Teller acuity cards or observation of fixation and follow. Strabismus and eye motility were noted. The refraction was measured in cycloplegia and funduscopy was performed. The distances between inner and outer canthus were measured. The follow-up examination was performed at the children's local hospital and data were retrieved from the medical records.

Results: Ninety nine infants were examined. The mean age at examination was 6 months (181 days) The main non-syndromic craniosynostosis was sagittal synostosis 68% (67/99). The prevalence of metopic synostosis was 17% (17/99), of unicoronal synostosis 14% (14/99) and lambdoid synostosis 1% (1/99). Preoperatively all infants had a visual behaviour normal for their age. The mean spherical equivalent was + 1.69 Diopters (D) in their right eyes (RE) and + 1.73 Diopters (D) in their left eyes (LE). Anisometropia ≥ 2 (D) was found in 4 infants and strabismus in 8. Strabismus was most common in children with unicoronal synostosis (62%). No infant had disc oedema or pale disc. The mean distance of inner and outer canthus was 22.6 mm and 53.5 mm, respectively.

Conclusion: In this cohort of infants with non-syndromic craniosynostosis, the visual behaviour was good and the refraction in most cases normal for age. Strabismus was most common in infants with unicoronal craniosynostosis. No child had disc oedema. The follow-up data at 6-12 months after surgery will be presented.



Rapid Fire + Poster Abstracts

RF 19

Unilateral ptosis is rarely amblyogenic

Sally Painter¹, Rehan Rajput²,
Manoj Parulekar¹

¹ Birmingham Childrens Hospital, Birmingham,
United Kingdom

² Birmingham Midland Eye Centre, Birmingham,
United Kingdom

Speaker: Sally Painter

Introduction: Severe unilateral ptosis is considered to carry a significant risk of amblyopia. Early surgery may be indicated to ensure optimum visual development, while delaying surgery for a few years until the lid structures are better developed can give better cosmetic outcomes.

Methods: Children undergoing ptosis surgery in a tertiary children's hospital under a single surgeon's care between 2008 and 2017 were included in this retrospective case-note review. Data was collected on the nature of the ptosis, confounding visual factors, visual acuity, treatment for amblyopia and indication for surgery.

Results: 138 children with unilateral ptosis underwent surgery at a mean age of 74 months. 41 (30%) children had amblyopia of which 12 (8.7%) had a sensory amblyopia secondary to ptosis. The remaining 29 had amblyopia secondary to a combination of anisometropia, strabismus or sensory causes other than ptosis. Of the children with amblyopia secondary to ptosis, this was treated with occlusion and surgery in 10 children, and with surgery alone in 2 cases. Amblyopia defined as an interocular difference of >0.2 LogMAR remained in 1/12 at final review.

Conclusion: Childhood ptosis rarely results in irreversible amblyopia and early surgery is indicated in a small minority of cases.

RF 20

Congenital Nasolacrimal Duct Obstruction preferred practice patterns among EPOS members

Maria Samouilidou¹, Asimina Mataftsi¹, Nikolaos Ziakas²

¹ 1st Department of Ophthalmology, AUTH, Thessaloniki, Greece

² 2nd Department of Ophthalmology, AUTH, Thessaloniki, Greece

Speaker: Samouilidou Maria

Introduction: This study was conducted to assess current management of CNLDO throughout Europe.

Methods: All EPOS members were invited in September 2017 by email to participate in an online anonymous questionnaire via surveymonkey platform. The questionnaire comprised of 20 questions with multiple available answers.

Results: 111 of 133 EPOS members (83,5%) responded. The majority use massage preoperatively, operate at the age of 12-15 months under general anaesthesia with probing as the primary procedure, and use dye to confirm patency intraoperatively. Diverse opinions were recorded regarding preoperative suggested massage periods, the use of fluorescein dye test to confirm obstruction, and the postoperative management.

In case of reoperation, the responses regarding timing of surgery, choice of procedure, use of tubes, and interval before tube removal, varied a lot.

Conclusion: There seems to be agreement in the main strategies of CNLDO management in Europe. Recorded diversities probably reflect absence of standardised guidelines and need for studies to establish evidence-based practice.





RF 21

Optic Nerve Head Abnormalities Associated with Congenital Fibrosis of Extraocular Muscles

Mervyn Thomas¹, Gail Maconachie¹,
Rob Dineen², Wai-Man Chan³,
Elizabeth Engle³, Irene Gottlob¹

¹ University of Leicester, Leicester, United Kingdom

² University of Nottingham

³ Harvard Medical School

Speaker: Mervyn Thomas

Introduction: We aimed to investigate optic nerve (ON) head morphology in patients with congenital fibrosis of extraocular muscles (CFEOM) using handheld spectral domain optical coherence tomography (SD-OCT).

Methods: Sixteen patients from eight families with CFEOM and sixteen age, gender and ethnicity matched healthy controls were recruited to this prospective, cross-sectional, observational study. Targeted next generation sequencing was performed to determine patient genotype. Handheld SD-OCT was used to acquire horizontal scans through the center of the optic disc in patients and controls. ON measurements included: horizontal disc diameter (DD), cup diameter (CD), cup depth, cup area, horizontal rim width (RW), rim area (RA) and nerve fiber layer (NFL) thickness.

Results: Mutations of KIF21A (n=4) or TUBB3 (n=7) were identified in 11/16 cases. DD and peripapillary NFL were significantly reduced in CFEOM patients compared to controls (p<0.005), with TUBB3 mutations most severely affected. RW and RA were significantly reduced in CFEOM (p<0.0001). KIF21A mutations were associated with a 66% reduction in RW while TUBB3 mutations were associated with a 57% reduction in RW. Cup diameter, depth and area were significantly increased in CFEOM (p<0.02). Fundus examination revealed a pseudo-normal appearance of optic disc. Situs inversus of retinal vessels was seen in five patients, of which four patients had the KIF21A (p.R954W) mutation.

Conclusion: Our study provides evidence of structural ON changes in patients with CFEOM. Both KIF21A and TUBB3 mutations had smaller optic nerves with reduced RW and NFL thickness. This study expands the phenotypic spectrum associated with CFEOM and shows that it extends beyond the motor nerves.

RF 22

Optic Disc Drusen in Children: Morphologic features using enhanced depth imaging optical coherence tomography

Filipa Teixeira¹, Raquel Marques¹, Sofia Mano¹, Rita Couceiro², Fatima Campos¹,
Filomena Pinto¹

¹ Hospital Santa Maria, Lisboa, Portugal

² Hospital de Vila Franca de Xira, Portugal

Speaker: Filipa Teixeira

Introduction: The morphological characteristics of optic disc drusen (ODD) on optical coherence tomography (OCT) have been in debate, and mainly they are described as a hyporeflective core surrounded by a hyperreflective margin. Hyperreflective ovoid mass-like structures located in the peripapillary circumference (termed PHOMS) have also been described as a different morphology pattern of ODD, although it is probable that they correspond to the peripapillary lateral bulging of retinal nerve fibres, as they are also found in patients with intracranial hypertension or optic nerve tumours. The aim of this study was to investigate morphologic features of ODD in children and understand if the presence of ODD and PHOMS influences peripapillary retinal nerve fiber layer (ppRNFL) thickness, using enhanced depth imaging optical coherence tomography (EDI OCT).

Methods: Retrospective observational study of children with ODD. All subjects underwent imaging with B scan ultrasonography, fundus photography, fundus auto-fluorescence (FAF), OCT of the pp-RNFL, and OCT scans through the optic nerve head with EDI-OCT. ODD were identified as circumscribed hyporeflective spheroidal elements located in front of the lamina cribrosa, fully or partially surrounded by a hyperreflective border. PHOMS were identified as hyperreflective ovoid structures located in the peripapillary circumference. Anatomic locations of ODD and PHOMS were assessed using EDI-OCT. Correlations between their locations and the sectors where the ppRNFL thickness was decreased were obtained through Chi-Square Test using SPSS Inc v25.

Results: Thirty-eight eyes of 20 children were analysed. ODD were bilateral in 90% of the cases. PHOMS were present in 89,5% of the patients. ODD and PHOMS were more commonly found in the nasal, supero-nasal and infero-nasal sectors. RNFL thickness was decreased more frequently in the supero-temporal (23,7%) and infero-temporal sectors (26,3%). A positive correlation was found between the presence of ODD and a RNFL thickness decrease in the nasal (p=0,018), supero-nasal (p=0,047) and infero-temporal (p=0,038) sectors. There was no correlation between presence of PHOMS and the location of decreased RNFL thickness.

Conclusion: EDI-OCT allowed morphological analysis of ODD and PHOMS. The presence of ODD was associated with a decreased thickness of the ppRNFL within the same location. On the contrary the presence of PHOMS was not related to a decrease in thickness of the neuro-retina.



Rapid Fire + Poster Abstracts

RF 23

Improved survival lead to higher ROP incidence in extremely preterm infants

Aylin Taner¹, Senait Tekle², Torsten Hothorn², Mark Adams³, Christina Gerth-Kahlert¹

¹ Department of Ophthalmology, University Hospital Zurich, Switzerland

² Institute for Epidemiology, Biostatistics, and Prevention, Zurich, Switzerland

³ Department of Neonatology, University Hospital Zurich, Switzerland

Speaker: Aylin Taner

Background: In Switzerland, the incidence of retinopathy of prematurity (ROP) stages 1 to 5 and of ROP requiring treatment is very low with 9.3 % and 1.2%, respectively. An increase in ROP treatment at our institution was observed after mid-2015. Our aim was to analyze possible reasons associated to this change to inform further management.

Methods: Retrospective analysis of all preterm infants born 7/2013 to 6/2017 with a gestational age (GA) < 29 completed weeks admitted to the local neonatal intensive care unit during the first 28 days of life. Data collection was based on the definition used for the Swiss Neonatal Network and consisted of 29 variables. Primary outcome was ROP treatment and secondary outcome was severest ROP stage (ROPmax). The remaining 27 variables were explanatory. Statistical analysis was performed using generalized additive models (GAM) in R.

Results: Significant predictors for ROPmax were GA, days of mechanical ventilation, and multiple births. A composite of severe comorbidities had no significant effect on ROPmax>0. Applying the GAM, GA was identified as the only significant risk factor for ROPmax (p-value < 0.01). This is in accordance with the decreased probability of death over time for infants born with a GA < 29 weeks during the study period.

Conclusions: Improved care and increased survival rate of extremely preterm infants resulted in an increased risk for ROP at our institution. Despite the increase, the incidence is still very low compared to other countries. No other additive factors were identified.

RF 24

Retinopathy of prematurity: frequency and associated risk factors in a large Greek cohort.

Stella Moutzouri¹, Aikaterini Seliniotaki¹, Parthena Theodoridou¹, Nikolaos Ziakas², Anna-Bettina Haidich³, Asimina Mataftsi¹

¹ 2nd Ophthalmology Department, Aristotle University of Thessaloniki, Thessaloniki, Greece

² 1st Ophthalmology Department, Aristotle University of Thessaloniki, Thessaloniki, Greece

³ Department of Hygiene, Aristotle University of Thessaloniki, Thessaloniki, Greece

Speaker: Stella Moutzouri

Introduction: This study aimed to determine the frequency and associated risk factors of retinopathy of prematurity (ROP) in a tertiary neonatal care unit in Northern Greece.

Methods: The medical records of infants screened for ROP from April 2004 to April 2018 in the 2nd University Department of Neonatology of Thessaloniki were retrospectively reviewed. ROP screening was performed according to U.K. screening guidelines (i.e. gestational age <32 weeks or birth weight <1501 grams) and in infants with increased comorbidity. The following neonatal risk factors [gestational age (GA), birth weight (BW), type of gestation, gender, respiratory distress syndrome, Apgar score, culture-proven sepsis, bronchopulmonary dysplasia, intraventricular haemorrhage, periventricular leukomalacia, necrotising enterocolitis, duration of oxygen supplementation (conventional ventilation, continuous positive airway pressure, head box, inhaled nitric oxide), need for blood transfusion] were assessed. Generalised estimating equations was used for statistical analysis.

Results: A total of 1416 infants were screened for ROP. Mean (standard deviation (SD)) GA and mean (SD) BW were 30.2 (2.2) weeks and 1369 (389.7) grams respectively. 231 infants bordered the screening criteria and were examined due to increased comorbidity. ROP developed in 265 (18.7%) infants, and treatment-requiring ROP (TR-ROP) in 42 (3.0%) infants, all of whom fell within screening criteria. Treated infants had significantly smaller GA and lower BW than those who were not (p<0.001). Statistical analysis revealed that GA [odds ratio(OR)=0.369, 95% confidence interval (CI) 0.227-0.601], BW (OR=0.991, 95% CI:0.986-0.995), inhaled nitric oxide (iNO) (OR=6.998, 95% CI:3.257-15.036) and transfusion of red blood cells (tRBC) (OR=1.301, 95% CI:1.135-1.492) were independently associated with the development of treatment-requiring ROP (TR-ROP) (all p<0.001).

Conclusion: ROP frequency in this tertiary neonatal care unit over a 14-year long period is similar to that reported in the developed world. The screening criteria used are safely applicable to our population. Small gestational age, low BW, iNO and tRBC are independent risk factors for TR-ROP.



RF 25

The role of platelet count in the pathogenesis of retinopathy of prematurity

**Anna Chmielarz-Czarnocińska¹,
Aneta Choręziak¹, Irmína Pawłowska²,
Dawid Szecht², Janusz Gądzinowski²,
Anna Gotz-Więckowska¹**

¹ Department of Ophthalmology, Poznań University of Medical Sciences, Poznań, Poland

² Department of Neonatology, Poznań University of Medical Sciences, Poznań, Poland

Speaker: Anna Chmielarz-Czarnocińska

Introduction: Thrombocytes may regulate the activity of vascular endothelial growth factor (VEGF), limiting neovascularization in retinopathy of prematurity (ROP). The aim of this study was to investigate the role of platelet count, thrombocytopenia (platelet count below 100G/L) and infections in the pathogenesis of ROP.

Methods: The retrospective study compared 76 patients who developed ROP requiring treatment (mean gestational age: 25±1,72 weeks, weight: 830±206g) and a control group – 87 patients with ROP that resolved spontaneously (mean gestational age: 28±2,07 weeks, weight: 1125±352g). Laser retinal photocoagulation (n = 47), injection of VEGF inhibitor (n=5) or both (n=24) were used as treatment methods. Further analysis concerned the patients treated: 52 patients treated once and 24 patients who required re-treatment. Peripheral blood platelet counts (at birth, before 31 weeks of postmenstrual age, before the diagnosis of ROP, before qualification for treatment and retreatment, before the treatment and retreatment), number of platelets transfusions and occurrence of early-onset (intrauterine) or late-onset (>7 days after birth) infections were abstracted.

Results: A statistically significant difference was found in the occurrence of thrombocytopenia (p=0,015) and median platelet counts (p=0,008; cases: median 325G/L, controls: median 401G/L) before the diagnosis of ROP and the presence of late-onset infection (p=0,007). There was no significant association with platelets transfusions (p=0,402) or early-onset infections (p=0,087). The ROC curve analysis showed that the value of platelets above 232G/L may promote spontaneous resolution of ROP. Multivariate logistic regression analysis suggested that the risk of ROP development increased with the number of days with thrombocytopenia (OR: 1,097; 95% CI: 0,99-1,21, p=0,052). Among cases statistically significant difference between patients once treated and patients that required re-treatment was found in platelet counts before the diagnosis of ROP (p=0,017; median 371G/L; 242G/L); platelet counts before first intervention (p=0,013; median 345G/L; 262G/L) and the number of transfusions (p=0,042).

Conclusions: The results of this study confirm the association between ROP development and its severity with platelet count. Higher platelet count before the diagnosis may induce a spontaneous resolution of ROP. Late-onset infections seem to be more significant in ROP development than intrauterine infections.

RF 26

The association between retinopathy of prematurity and ocular growth

**Dimitrios Kardaras¹, Eleni Papageorgiou¹, Katerina Gaitana², Ioanna Grivea²,
Vasileios Dimitriou³, Evangelia Tsironi¹**

¹ Department of Ophthalmology, University Hospital Larissa, Greece

² Neonatal Intensive Care Unit, University Hospital Larissa, Greece

³ Department of Mathematics, Aristotle University, Thessaloniki

Speaker: Kardaras Dimitrios

Introduction: To prospectively investigate the association between retinopathy of prematurity (ROP) and ocular growth in premature infants during the earliest weeks of life.

Methods: Premature infants in the national ROP screening program were recruited and examined at 1- or 2-week intervals between 30 and 38 weeks' postmenstrual age. At each examination, the presence, stage and zone of ROP were recorded along with axial length (AL), central corneal thickness (CCT), and weight gain. Biometric parameters were measured by A-scan biometry. Study variables included gestational age (GA), birth weight (BW), AL, CCT, weight gain, relative weight (RW), and dif_AL, dif_CCT and dif_weight, which is the difference between two consecutive recordings of the same infant. Multiple regression analysis models were used to determine the association between the study variables and ROP.

Results: One hundred infants with GA between 24 and 35 weeks (30.04±2.13), and BW between 550 and 2060 gr (1251.45±317.19) were included in the study. The rate of growth in AL was lower in infants with ROP (0.11 mm/week) than in preterm infants without ROP (0.24 mm/week). The rate of CCT decrease is lower in preterm infants with ROP (10.93 µm/week) than in preterm infants without ROP (16.11 µm/week), resulting in different final CCT at the 38th postmenstrual week (571.52±37.05 µm in preterm infants with ROP and 541.85±77.56 µm in preterm infants without ROP). Dif_AL, dif_CCT and RW were the most appropriate variables to detect the optimal threshold points that discriminate ROP: Weekly increase of AL<0.095 mm, weekly reduction of CCT<0.5µm or weekly weight gain<7% are associated with ROP development.

Conclusion: ROP is associated with arrested ocular development, as eyes of premature infants with ROP have shorter axial lengths and thicker corneas than eyes of premature infants without ROP. The non-invasive ultrasound examination of AL and CCT can enhance our understanding of the premature eye growth and the development of ROP.



Rapid Fire + Poster Abstracts

RF 27

Results of treatment of retinopathy of prematurity in Poland, a single center analysis

Anna Chmielarz-Czarnocińska¹, Marta Pawlak¹, Marcin Stopa², Dawid Szecht³, Jan Mazela⁴, Anna Gotz-Więckowska¹

¹ Department of Ophthalmology, Poznań University of Medical Sciences, Poznań, Poland

² Department of Ophthalmology. Chair of Ophthalmology and Optometry

³ Chair and Department of Neonatology

⁴ Department of Neonatology and Infectious Diseases

Speaker: Anna Chmielarz-Czarnocińska

Introduction: This study aimed at analyzing the results of retinopathy of prematurity (ROP) treatment in Poznań medical center, which comprises of the largest obstetric hospital in Poland and constitutes a reference center for ROP treatment.

Methods: The data from 85 patients treated for retinopathy of prematurity from November 2015 to December 2017 were analyzed, assessing the anatomical results of the treatment. In 32 patients who remained under constant control of Outpatient Clinic for Preterm Infants of University Clinical Hospital no. 1 in Poznań long-term anatomical and functional results were assessed.

Results: In the period from November 18, 2015 to December 31, 2017, ROP was diagnosed in 234 patients. 165 eyes were treated in 85 (36.3%) children - 59 born in the Gynecology and Obstetrics Clinical Hospital of the Poznań University of Medical Sciences and 26 from other medical centers (external patients). In the first stage of treatment 58 children (113 eyes) underwent photocoagulation of the retina with a diode laser, and 27 children (52 eyes) were given intravitreal injections of a VEGF inhibitor (ranibizumab). Due to the lack of remission or recurrence of the disease 56 eyes of 29 patients (34.1%) required re-treatment: 27 eyes of 14 patients (48.3%) treated in the first stage with laser therapy and 29 eyes of 15 patients (51.7%) treated with ranibizumab injections. In 50 eyes (89.3%) of 25 patients remission was observed after the second line of treatment, while 6 eyes (10.3%) of 4 patients required vitrectomy because the disease progressed to the stages where retinal detachment occurred. The retinal reattachment was obtained in 3 eyes. After the treatment of ROP, 32 patients born in Gynecology and Obstetrics Clinical Hospital remained under constant control of the Outpatient Clinic for Preterm Infants. In this group 62 eyes were treated with different schemes. Visual responses were observed in 30 patients, in two patients they were doubtful and most likely resulted from optic nerve atrophy caused by concomitant systemic diseases.

Conclusions: 1. The anatomical and functional results obtained in our medical center in 2016-2017 are better compared to those in 2011-2015. 2. Despite significant progress in the diagnosis and treatment options for ROP, the choice of a proper therapy still remains a challenge.

RF 28

Informativeness of optical coherence tomography-angiography in children with active stages of retinopathy of prematurity

Irina Trifanenkova, Alexandr Tereshchenko

Kaluga branch of FG AU «NMIC «MNTK «Eye Microsurgery» named after acad. S.N. Fedorov», Kaluga, Russia

Speaker: Trifanenkova Irina

Introduction: Purpose of our is to reveal the informative value of optical coherence tomography-angiography for the retinal vessels condition assess in children with active retinopathy of prematurity.

Methods: 14 patients (28 eyes) with different stages of active ROP at the age of 4-9 weeks (31-38 weeks of post-conceptual age) were studied. Stage 3 of classic ROP in zone I was revealed in 3 patients, in zone II - in 1 patient, 4A stage in the zone II - in 4 children. Aggressive posterior ROP were diagnosed in 7 children, in 3 - at the stage of early clinical features, in 4 - at the stage of manifestation. In addition to the standard examination patients underwent digital retinoscope with digital morphometry, FA, SOCT and OCT-A.

Results: In children with 3 and 4A stages of active ROP in the zone II, OCT-A revealed no pathological changes in the capillary bed in the central zone of the retina. In patients with 3 stage of active ROP in the zone I plots of epiretinal neovascularization was defined within the foveal region. At the stage of early clinical features of aggressive posterior ROP, intraretinal neovascular complexes and multiple arterio-venous shunts were visualized in the superficial vascular plexus in all segments within the perifovea. At the stage of manifestation of aggressive posterior ROP a gross disturbance of the architectonics in the superficial and deep vascular plexuses was determined, dilated and tortuous vessels of the upper temporal vascular arcade were revealed, during which multiple intra- and epiretinal neovascular complexes were spread.

Conclusion: OCT-A is a valuable method of diagnosis in infants with active stages of ROP. Identified pathological changes require further clinical research.



RF 29

Comparison of the optic nerve head parameters and RNFL in premature and full term children with OCT

Yaroslava Wenner¹, Kira Kunze¹,
Vanessa Brauer¹, Volker Besgen¹,
Rolf F. Maier², Walter Sekundo¹

¹ Department of Ophthalmology, Philipps-University Marburg, Germany

² Department of Paediatrics, Philipps-University Marburg, Germany

Speaker: Yaroslava Wenner

Introduction: To compare parameters of the optic nerve head (ONH) in preterm and full term children measured with OCT and evaluate their relationship with birth weight (BW), gestation age (GA), ROP and neuronal disorders.

Methods: ONH and peripapillary nerve fiber layer (RNFL) were examined with Optovue-100 OCT in 5-15 year old preterm and full term children. RNFL thickness and ONH parameters of the both groups were compared and correlation with birth weight, gestational age, ROP and neurological disorders in preterms was evaluated.

Results: 106 children were included in the study, 55 of them were prematurely born with mean GA 29.6 ± 3.8 weeks, BW 1523.8 ± 732.3 g. Mean age of preterm children was 9.3 ± 2.5 , of full term children 9.4 ± 3.2 years.

RNFL thickness was significantly lower in preterm in comparison to full term children in all but temporal quadrants. Cup area (0.47 ± 0.48 mm² vs. 0.29 ± 0.37 mm², $p=0.036$), cup volume (0.10 ± 0.15 mm³ vs. 0.04 ± 0.06 mm³, $p=0.012$), cup/disc area (0.25 ± 0.25 vs. 0.14 ± 0.15 , $p=0.009$), horizontal (0.49 ± 0.31 vs. 0.38 ± 0.27 , $p=0.041$) and vertical CDR (0.44 ± 0.29 mm vs. 0.33 ± 0.24 mm, $p=0.034$) were significantly larger in preterm children. Rim area was significantly smaller in preterm children (1.40 ± 0.62 mm vs. 1.73 ± 0.56 mm, $p=0.005$).

In preterm children there was a significant positive correlation of GA and BW with the superior quadrant and overall RNFL thickness and a negative correlation with cup area, cup volume and cup/disc horizontal ratio. ROP had no influence on RNFL or ONH whereas neuronal disorder was the strongest predicting factor for RNFL thinning ($p<0.05$) in all but temporal quadrants in multiple regression analysis.

Conclusion: Due to a lower RNFL thickness ONH of preterm children possesses significantly smaller rim area and larger optic cup. Neuronal disorders were the strongest factor causing RNFL thinning. These facts should be taken into account before diagnosis of glaucoma in preterm children is made.

RF 30

Retinal ganglion cells complex in preterm children at childhood

Ana Ortueta-Olartecoechea, Jose Luis Torres-Peña,
Alicia Muñoz-Gallego, Cañas-Zamarra Ignacio, de
la Cruz-Bértolo Javier, Pilar Tejada-Palacios

Hospital Universitario 12 de Octubre, Madrid, Spain

Speaker: Ana Ortueta-Olartecoechea

Introduction: The improvement of neonatal care has made it possible that very preterm children survive. However, these children can develop serious medium and long term sequels. Due to the development of new technics such as the optical coherence tomography (OCT) we are now able to study precise retinal structures as the ganglion cell complex, that represents the first neuron of the visual system and can be disrupted due to the preterm birth just like other structures of the central nervous system. This complex encompass three layers in the retina: the inner-plexiform layer (IPL), the ganglion cell layer (GCL) and the macular retinal nerve fiber layer (mRNFL).

Methods: We present a transversal study in which 132 preterm children were studied and the GCC has analyzed. They were between 6 and 11 years old at the moment of examination and underwent an OCT (TOPCON 3D OCT-2000) between 2013 and 2016. The data was analyzed with SPSS version 18.

Results: The study population had a mean visual acuity of 0.87 ± 0.16 decimal scale and a mean spherical equivalent of $+1.67 \pm 1.67$ diopters. Mean age at the time of the exploration was 6.12 ± 1.36 years old, mean gestational age (GA) was 28.85 ± 2.57 weeks and mean birth weight (BW) was 161.2 ± 357.39 g. Concerning to race, 78.8% of the patients were Caucasian followed by Hispanic with 14.4% and African with 6.8 %. ROP was present in 32 patients (58 eyes), 25 patients have it bilaterally. Of the patients with ROP, 36 eyes had mild ROP (62%) and 22 had sever ROP (38%) of which 5 (8.6%) needed laser treatment. ROP plus was present in 4 patients (6.8%).

The difference in GCC thickness among the different ethnic group was not significant. The patients with ROP, we found differences in the average GCL-IPL compared to those without ROP. There were not differences concerning ROP severity. We found that both the BW, the GA and the spherical equivalent (SE) have a directly proportional relation with all the measurements of GCL and mRNFL thickness.

When doing a multivariate regression analysis, 15% of the total GCC thickness change depended on BW and GA adjusted by SE.

Conclusions: Our study shows that GA and BW have a directly proportional relation with GCC thickness. It is important to take into consideration the SE value when analyzing this data, as it can also modify the GCC thickness. We need more studies to look for other factors that may affect this retina layer in a higher amount.



Rapid Fire + Poster Abstracts

RF 31

Retinal ganglion cells complex and neonatal determinants: an optical coherence tomography study in very preterm children at school-age

Ana Ortueta-Olartecoechea, Jose Luis Torres-Peña, Alicia Muñoz-Gallego, Cañas-Zamarra Ignacio, de la Cruz-Bértolo Javier, Pilar Tejada-Palacios
Hospital Universitario 12 de Octubre, Madrid, Spain

Speaker: Ana Ortueta-Olartecoechea

Introduction: The improvement of neonatal care has had a major impact in the increased survival rate of very preterm (VPT) newborns, and in the decreased prevalence of some conditions, such as cerebral palsy. Nonetheless, VPT children have a higher risk of developing neurodevelopmental impairments than their term peers, including ophthalmological impairments. The optical coherence tomography (OCT) is a new technique that enables ophthalmologists to study more accurately retinal structures such as the ganglion cell complex (GCC). The GCC is the first neuron of the visual system and we hypothesised it can be disrupted due to preterm birth. The aim of this study was to describe GCC thickness as a function of neonatal determinants in very preterm children at school age.

Methods: This is a cross-sectional study based on a follow-up cohort of very preterm children (gestational age < 32 weeks and/or birth weight < 1500 g) assessed at school-age. Children underwent an OCT exam with TOPCON 3D OCT-2000. We measured the thickness of the three layers in the retina: the inner-plexiform layer (IPL), the ganglion cell layer (GCL) and the macular retinal nerve fiber layer (mRNFL). We compared the three layers OCT measurements by gestational age, birthweight, ROP screening and treatment history.

Results: The study population included 132 children born VPT. At the time of OCT exam, mean age was 6.12 ± 1.36 years, mean visual acuity 0.87 ± 0.16 decimal scale and mean spherical equivalent (SE) $+1.67 \pm 1.67$ diopters. As for neonatal determinants, mean gestational age (GA) was 28.85 ± 2.57 weeks and mean birth weight (BW) 1161.2 ± 357.39 g. As for ethnic origin, 78.8% were Caucasian, 14.4% from S/C America and 6.8 % from Africa. Any grade of ROP was present in 32 patients (58 eyes), bilateral in 25 patients: 36 eyes had mild ROP (62%) and 22 had severe ROP (38%) of which 5 (8.6%) needed laser treatment. No significant difference in GCC thickness was found among ethnic groups. Patients with ROP showed differences in the average GCL-IPL compared to those without ROP. No differences were found related to ROP severity. BW, GA and SE showed a positive correlation with all GCL and mRNFL thickness measurements. In a multivariate regression analysis, BW, GA and SE explained 15% of variation in total GCC thickness.

Conclusions: Our study shows that GA and BW have a direct proportional relation with GCC thickness, and that it is important to consider SE values when interpreting OCT data.

RF 32

Using in vivo confocal microscopy and anterior segment optical tomography in nephropathic cystinosis

Anita Csorba¹, Erika Maka¹, Nóra Szentmáry¹, Miklós Resch¹, Attila Szabó², Zoltán Zsolt Nagy¹

¹ Department of Ophthalmology, Semmelweis University, Budapest, Hungary

² 1st Department of Pediatrics, Semmelweis University, Budapest, Hungary

Speaker: Anita Csorba

Introduction: Cystinosis is a very rare storage disease. Due to mutation of the CTNS gene the cystinosis transporter protein is damaged and cystine amino acid accumulates in lysosomes. Accumulated cystine forms crystals and appears in various tissues, mostly affects the kidneys and the eyes. Because of dense deposition of crystals, patients suffer from extreme photophobia.

Purpose: To introduce examination results of children with infantile nephropathic cystinosis at Department of Ophthalmology, Semmelweis University.

Methods: We analyzed anterior segment optical coherence tomography (AS-OCT) and in vivo confocal microscopy (IVCM) images of cornea (mean age: 17.6 years; SD: 7.23) (4 men, 1 women). According to the AS-OCT images we identified precisely the location of the crystal deposits. Using IVCM, the density of the crystals was evaluated in different layers.

Results: Examinations were feasible in spite of photophobia in every patients. Except endothelium, crystal deposits were observed in all layers of the cornea. In children crystals were located predominantly in the anterior stroma in contrast with adults, where the deposits were mostly in the posterior stroma.

Conclusion: IVCM and AS-OCT are suitable for morphological representation of cystine crystals in each corneal layer. They are reliable methods to evaluate the severity of corneal involvement and to follow the effectiveness of local therapy. There is a difference in location of crystals between adults and children.



RF 33

Comparison of quantitative measurement of foveal avascular zone and macular vessel density in eyes of children with chronic kidney disease and healthy controls

Hajnalka Horváth¹, Cecília Czakó¹, Bettina Tábori¹, Gábor László Sándor¹, Flóra Tóth¹, Attila Szabó², Zoltán Zsolt Nagy¹, Erika Maka¹

¹ Department of Ophthalmology, Semmelweis University, Budapest, Hungary

² 1st Department of Pediatrics, Semmelweis University, Budapest, Hungary

Speaker: Hajnalka Horváth

Introduction: To assess macular vessel density (VD) and foveal avascular zone (FAZ) in eyes of children with chronic kidney disease using optical coherence tomography angiography (OCTA) and to compare potential pathologic changes in this population to healthy controls.

Methods: 20 right eyes of 20 children with chronic kidney disease and 27 right eyes of 27 healthy controls underwent OCTA imaging (RTVue-XR Avanti; Optovue, Fremont CA, USA) to measure macular VD, FAZ and foveal retinal thickness. Retinal VD was measured in the central macula with a radius of 3 mm. In both study groups, age, gender, best corrected visual acuity (BCVA), axial length (AL), corneal refractive power (K) and central corneal thickness (CCT) were recorded. The difference of the aforementioned parameters between children with chronic kidney disease and healthy controls was assessed using Mann-Whitney U test.

Results: No significant difference in AL, BCVA, corneal parameters (K, CCT) was observed between patients with kidney disease and controls ($p > 0.05$). The macular vessel density was lower in the renal failure group than in the control group in the whole macular region (51.3345 % (SD: ± 3.0484) vs. 54.2159% (SD: ± 1.4564), $p < 0.01$) as well as in the parafoveal scans (53.5425 % (SD: ± 3.35408) vs. 56.5844 % (SD: ± 1.787), $p < 0.01$). There was no significant difference in FAZ and foveal retinal thickness between the two study groups.

Conclusion: The study found that OCTA reveals subnormal retinal vessel density in the whole macular region of children with chronic kidney disease. Further studies are needed to determine the clinical relevance of this finding.

RF 34

Wide-Field Autofluorescence Imaging for Follow-up of LCHAD Deficiency Chorioretinopathy

Eva Roomets, Tero Kivelä

¹ Tallinn Children's Hospital, Tallinn, Estonia

² Helsinki University Central Hospital, Helsinki, Finland

Speaker: Eva Roomets

Introduction: Long-chain 3-hydroxy-acyl-CoA dehydrogenase (LCHAD) deficiency belong to defects of mitochondrial fatty acid β -oxidation, the main energy producing pathway during prolonged exercise and fasting. While LCHAD deficiency can be effectively treated with a high-carbohydrate, low-fat diet and avoidance of fasting, progressive chorioretinopathy remains the major long-term concern of the patients. It is characterized by an early onset granularity of the retinal pigment epithelium in the posterior pole, which progresses towards periphery and may lead to a circumscribed chorioretinal atrophy.

Methods: Nine Finnish patients (aged 6-16 years, median age 9 years) with relatively early diagnosis (aged 0 -11 months, median age 5 months) of LCHAD deficiency caused by the homozygous G1528C common mutation and good compliance of the dietary therapy were included. Wide-field fundus autofluorescence (FAF) images were obtained at least in two follow up visits every two years.

Results: Six of nine patients showed pigmentary abnormalities on their first FAF images, which progressed only mildly or not at all. The decreased FAF was restricted within the vessel arcades in two patients, and extended outside the posterior pole in four. In one patient, a circle of increased FAF was seen at the border of the posterior pole. Three patients displayed normal uniform autofluorescence during their follow-up time.

Conclusion: Our data are promising and suggest that good compliance of the dietary therapy started during the first months of life may delay or even halt the progression of the chorioretinopathy. Wide-field FAF imaging allows more detailed assessment of the extent and progression of the pigmentary changes and thus improve monitoring and optimization of the therapeutic protocols.



Rapid Fire + Poster Abstracts

RF 35

Foveal avascular zone and macular vessel density in eye of healthy children

Bettina Tabori¹, Cecília Czakó²,
Hajnalka Horváth², Emília Kiss²,
Gábor László Sándor², Flóra Tóth²,
Zoltán Zsolt Nagy², Erika Maka²

¹ Ferenc Jahn Hospital, Budapest, Hungary

² Department of Ophthalmology, Semmelweis University, Budapest, Hungary

Speaker: Bettina Tabori

Introduction: In ophthalmology, more and more imaging processes are coming into view so as to help the diagnosis of certain ophthalmic diseases. The different imaging processes are applied for adults on a daily basis; however, a small amount of data for children has been gathered so far.

Purpose: To assess macular vessel density (VD) and foveal avascular zone (FAZ) in eyes of healthy children.

Methods: 27 right eyes of 27 healthy children (mean age: 9 years, SD: ± 2.1) (18 girls/9 boys) underwent optical coherence tomography-angiography (OCTA) imaging (RTVue-XR Avanti; Optovue, Fremont CA, USA) to measure whole and parafoveal macular VD, FAZ and foveal retinal thickness. Retinal VD was measured in the central macula with a radius of 3 mm. Age, gender, best corrected visual acuity (BCVA), axial length (AL), corneal refractive power (K) and central corneal thickness (CCT) were recorded.

Results: The mean values received includes FAZ: 0.2792 mm² (SD: ± 0.08) the vessel density in the whole macular region: 54.2159% (SD: ± 1.4564) and in parafoveal region: 56.5844 % (SD: ± 1.787) and foveal thickness: 241.037 μ m (SD: ± 15.7076). There were no significant correlations between the biometric data (AL, K, CCT) and OCTA findings (FAZ, VD).

Conclusion: We found that OCT angiography could be performed above 6 years of age. We can collect informations about the vasculature of the macula with this non-invasive imaging technique.

RF 36

OCTA findings in patients with Stickler syndrome compared to normal population

Dóra Somodi, Cecília Czakó,
Hajnalka Horváth, Emília Kiss,
Gábor László Sándor, Bettina Tabori,
Flóra Tóth, Zoltán Zsolt Nagy, Erika Maka

Semmelweis University, Department of
Ophthalmology, Budapest, Hungary

Speaker: Dóra Somodi

Purpose: To evaluate the size of foveolar avascular zone (FAZ), vessel density and foveal thickness using optical coherence tomography angiography (OCT-A) in patients with Stickler syndrome and to compare the results with the normal population.

Methods: 23 eyes of 13 patients were included into this study who had genetically confirmed diagnosis of Stickler syndrome or were clinically suspicious for the disease. All patients were assessed including axial length, keratometry, central corneal thickness, best corrected visual acuity (BCVA). OCT-A imaging (RTVue-XR Avanti; Optovue, Fremont CA, USA) was performed to measure FAZ size, vessel density in the central macula with a radius of 3 mm and foveal thickness. The results were assessed compared to our control group with no pathology.

Results: Axial length was significantly longer in patients with Stickler syndrome compared to the control group (26.34 mm vs. 22.95 mm, $p=0.0001$). Regarding the BCVA, significant difference was also detected between the Stickler vs. control group (0.72 (SD: ± 0.30) vs. 1.06 (SD: ± 0.13), $p<0.01$). OCT-A showed that the foveolar avascular zone was significantly smaller in Stickler patients (0.1831 mm² (SD: ± 0.0828) vs. 0.2792 mm² (SD: ± 0.08), $p=0.0002$), while vessel density was decreased both for the whole examined area (48.0148 % (SD: ± 3.9025) vs. 54.2159% (SD: ± 1.4564), $p<0.01$) and the parafoveal area (49.8496 % (SD: ± 4.9040) vs. 56.5844 % (SD: ± 1.787), $p<0.01$), furthermore foveal thickness was increased in patients with Stickler syndrome compared to controls (253.3478 μ m (SD: ± 22.9557) vs. 241.037 μ m (SD: ± 15.7076), $p=0.0153$).

Conclusion: Optical coherence tomography angiography provides further information of characteristic changes in eyes with Stickler syndrome.



RF 37

Diagnosing retinal laser injuries using near-infrared autofluorescence

James Neffendorf¹, Samantha De Silva¹,
Daniel Jackson¹, Johannes Birtel²,
Philip Herrmann², Peter Charbel Issa¹

¹ Oxford Eye Hospital, Oxford University Hospitals, Oxford, United Kingdom

² Department of Ophthalmology, University of Bonn, Bonn, Germany

Speaker: Daniel Jackson

Introduction: Laser induced retinopathy (LIR) is increasing in frequency due to the easy availability of handheld toy lasers on the internet. These lasers often have an output power over 5mW, meaning they have the potential to cause irreversible retinal damage. Children are often difficult historians and parents may feel guilt in admitting laser usage by their children. Therefore it is thought that LIR is underreported. Furthermore, clinical signs of LIR may be subtle, and missed on standard clinical examination. Near-infrared autofluorescence (NIR-AF) is a novel way of imaging macular disease by delineating the melanin pigment within the retinal pigment epithelium (RPE).

Methods: We present the imaging characteristics of 9 children with LIR that presented to the Oxford Eye Hospital (Oxford, UK), and Department of Ophthalmology, Bonn (University of Bonn, Germany). All children underwent full clinical examination, fundus photography (FP), spectral domain optical coherence tomography (sd-OCT), regular short wave autofluorescence (SW-AF) and NIR-AF.

Results: In all cases, NIR-AF in combination with sd-OCT resulted in the best clinical representation of the laser injury. In some cases, FP showed what appeared to be a normal fundus, despite underlying LIR.

Conclusion: NIR-AF is an important diagnostic tool in revealing the topographic nature and full extent of LIR. SW-AF does not have the ability to penetrate macular pigment and therefore is not the best imaging modality in LIR. The pattern of LIR on NIR-AF shows how saccadic movements often result in multiple small RPE defects. We highlight the importance of this diagnosis and the importance of educating the public of this growing public health issue.

RF 38

Multimodal retinal imaging in pediatric traumatic maculopathy

Eleni Papageorgiou, Fotini Xanthou,
Nikolaos Voutsas, Sofia Androudi,
Evangelia Tsironi

Department of Ophthalmology, University Hospital Larissa, Greece

Speaker: Eleni Papageorgiou

Introduction: To present the Optical Coherence Tomography Angiography (OCTA) findings in four cases of pediatric traumatic maculopathy: two cases of pediatric commotio retinae and two cases of macular hole from a laser pointer.

Methods: A 6-year-old boy and a 3-year-old girl presented for evaluation following blunt ocular trauma. A 9-year-old boy and a 15-year-old boy presented for investigation of unilateral decreased vision. All patients underwent visual acuity (VA) testing, slit-lamp exam, fundus photography, swept-source spectral domain optical coherence tomography, and OCTA.

Results: The children with the closed globe trauma presented with Berlin edema and experienced an immediate reduction in VA of 0.9 and 0.7 logMar respectively. On follow-up, VA improved to 0.15 logMar in both cases and RPE irregularities developed in the posterior pole. OCT revealed hyperreflectivity of the RNFL, disruption of the ellipsoid zone and the RPE, and retinal thinning. Loss of choriocapillaris, reduced vessel density in the outer retina and enlargement of the foveal avascular zone in the deep retinal layers were identified in OCTA. The 9-year-old boy presented with a VA of 0.8 logMar in the left eye and funduscopy revealed a macular hole with a hypo-pigmented atrophic area inferiorly. OCT and fundus autofluorescence showed a full thickness macular hole, with central hypo-autofluorescence surrounded by a ring of hyper-autofluorescence. OCTA revealed choriocapillaris ablation just beneath the crater of macular hole. The 15-year-old boy presented with a VA of 0.9 logMar in the right eye. Funduscopy and OCT showed a partial thickness macular hole with increased perifoveal pigmentation and disruption of the ellipsoid zone and the RPE. In OCTA there was enlargement of the foveal avascular zone and absence of the choriocapillaris in the foveal area. Both boys reported playing with a green laser pointer and looking repeatedly into the laser beam.

Conclusion: OCTA is a noninvasive imaging modality capable of evaluating and characterizing the microvascular alterations of pediatric traumatic maculopathy. Blunt ocular trauma and unauthorized laser pointer availability pose an emerging serious threat in public eye health, particularly in the pediatric population.



Rapid Fire + Poster Abstracts

RF 39

Macular OCT in Early-Onset Severe Retinal Dystrophies

Edouard Malandain, Olivia Zambrowski, Marc Abitbol, Dominique Bremond-Gignac, Matthieu Robert

Service d'ophtalmologie, Hôpital Necker Enfants malades, AP-HP, Paris, France

Speaker: Malandain Edouard

Introduction: Several recent articles have suggested that normal macular OCT in the context of a nystagmus in an infant could obviate the need of a full-field ERG to rule out a retinal dystrophy. Here we look at the earliest features of retinal OCT in cases of early-onset severe retinal dystrophy (EOSRD).

Methods: All files of children born between 2008 and 2014 with a confirmed diagnosis of EOSRD were retrospectively reviewed. Cases of Leber congenital amaurosis, cone dysfunction syndromes and congenital stationary night blindness were not considered. Cases with no early and high quality foveal OCT scans were excluded. Inclusion criteria comprised a strictly pendular nystagmus and severely reduced but still identifiable photoreceptor function on full-field ERG. The age of onset of the nystagmus, symptoms, best visual corrected acuity, cycloplegic refractive error, fundus aspect, were noticed.

Results: Nine children were included (6 boys and 3 girls). Age at nystagmus onset ranged from 1 month to 18 months (mean= 5.4 months). At first examination, only 3 children exhibited photophobia (33%), while hemeralopia was never identified. Fundus appearance was normal in all cases, except for 3 cases (=33%) with various abnormalities (non-specific peripheral pigmentation, isolated attenuated vessels, macular atrophy). BVCA at last examination ranged from 1.0 to 0.4 LogMAR, and refractive errors from -5.0D to +5.5D.

Analyzed OCT scans were performed on average at 5 years (+/- 1.4 years); they revealed in 4 cases (44%) typical abnormalities of the ellipsoid zone (EZ) band: foveal disruption in 1 case, and irregularities in 3 cases. However, 5 of the 9 patients (56%) demonstrated unaltered outer retinal structure, with preservation of the inner segment ellipsoid layer and outer nuclear layer, but with a subtle thickening of the foveal ellipsoid zone band for 4 patients.

Conclusion: Conventional OCT scan of the macula can be performed under age 1 year and after age 3, even when the child presents a nystagmus and photophobia. Our findings suggest that a preservation of the EZ band cannot discard a retinal dystrophy, while a subtle thickening of the EZ band, difficult to assess, may be the first sign of EOSRD on OCT. The role of global ERG in the diagnosis process of pendular nystagmus therefore remains crucial.

RF 40

Invisible Retinoblastoma: the role of OCT

Marie-Claire Gaillard, Susan Houghton, Christina Stathopoulos, Francis L. Munier

Jules-Gonin Eye Hospital, University of Lausanne, Lausanne, Switzerland

Speaker: Marie-Claire Gaillard

Introduction: Optical coherence tomography (OCT) is a powerful non-invasive imaging tool that has already revolutionized the diagnostic and therapeutic approach in many retinal diseases. Its resolution allows an in vivo histological section and can reveal small tumors even before clinical evidence on ophthalmoscopy. We present the role of OCT in detection and management of invisible retinoblastoma.

Methods: Since June 2012, hand-held SD- OCT (spectral domain Optical Coherence Tomography) of retro-equatorial foci, the optic head nerve and macula, is systematically performed under anesthesia in children treated and followed for Rb.

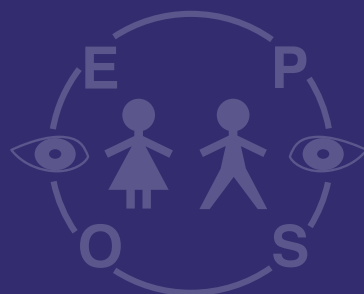
Results: The infraclinical primary tumors were in general diagnosed in familial Rb patients, initially appearing as round lesions with an iso-reflective nuclear layer located in the outer retina. Overlaid by a preserved inner retina, the mass presents a well-defined circular posterior border that appears to spare the photoreceptor layer.

Infraclinical recurrences are smaller than 400 μ m and more easily detected in regression types 4 and 2, with highly calcified lesions of type 3 being more difficult to record. In diffuse relapse with vitreous seeding OCT can reveal the deposit of an invisible seed in the optic nerve cup or foveolar depression. OCT can also influence therapeutic decisions in the case of extension into the vitreous, intravitreal injections of Melphalan being recommended for this situation. Regression type 0, Rb foci that are invisible after chemotherapy, are revealed as elongated tumors only detectable on OCT. Only careful monitoring with OCT could prove the inactivity of these tumors.

Conclusion: Our data strongly support the role of OCT in the modern management of retinoblastoma. OCT is not only invaluable for the early detection of lesions and therapeutic decision making, but also in the monitoring of tumor response, particularly in the case of extension towards the macula or optic nerve head.



Poster Abstracts





Eye care, Imaging, Nystagmus, Glaucoma

- P 1** **Bela Csakany (Hungary):** Full-length OCT biometry examination of healthy children
- P 2** **AbdulRahman Fagih (Saudi Arabia):** Evaluation of the PlusoptiX Photo screener in the examination of children with Intellectual Disabilities
- P 3** **Eirini Kostopoulou (Greece):** Longterm surgical outcomes in children with primary congenital glaucoma
- P 4** **Ana Sofia Lopes (Portugal):** Infantile congenital nystagmus and botulinum toxin: a hypothesis to consider?
- P 5** **Lina Raffa (Saudi Arabia):** Eye Care Survey in a Special Needs School in Jeddah
- P 6** **Sujata Sarda (USA):** Healthcare Resource Utilization and Costs Associated With Infectious Conjunctivitis: A US Claims Analysis
- P 7** **Filipa Teixeira (Portugal):** Pediatric examination under anesthesia – What's the value?
- P 8** **Filipa Teixeira (Portugal):** Baerveldt Attached to XEN: A New Technique for Secondary Paediatric Glaucoma
- P 9** **Jose Torres-Peña (Spain):** Roll of the optical coherence tomography in the diagnosis of leukoencephalopathy associated with mutation in POLR1C
- P 10** **Tamás Zeffer (Hungary):** Case report: Conventional and new imaging techniques of fovea plana in children

Orbit, Lacrimal, Eyelid

- P 11** **Martina Delle Fave (Belgium):** A case of congenital lacrymal gland agenesis in a patient presenting BPES syndrome
- P 12** **Fabienne Fierz (Switzerland):** Outcome in congenital ptosis surgery
- P 13** **Monica Gimeno-Carrero (Spain):** Management of lacrimal alterations in a child with Fraser syndrome
- P 14** **Pablo Nadal Iglesias (United Kingdom):** Division of lid adhesions in a case of Ankyloblepharon-Ectodermal Defects-Cleft Lip syndrome
- P 15** **Christopher King (United Kingdom):** Craniosynostosis in Alagille syndrome: A case series and review of the literature
- P 16** **Olga Lukáts (Hungary):** Encephalocraniocutaneous lipomatosis (diagnosis, differential diagnosis, treatment, follow up)
- P 17** **Otto Alexander Maneschg (Hungary):** Clinical features and surgical treatment for progressive bilateral ptosis in Kearns-Sayre syndrome: a case report
- P 18** **Iren Szalai (Hungary):** Treatment of congenital nasolacrimal duct obstruction in children by monocanalicular intubation with a lacrimal duct stent
- P 19** **Alexandr Tereshchenko (Russia):** Digital images of the fundus under inferior oblique weakening surgery
- P 20** **Carla Villena (Spain):** Eyelid reconstruction in Barber-Say syndrome



Poster Abstracts

Anterior segment

- P 21 Maria Bausz (Hungary):** Imaging in Axenfeld-Rieger Syndrome
- P 22 Claire Hartnett (United Kingdom):** New PEX11B mutation in 3 siblings with bilateral congenital cataract
- P 23 Daniel Jackson (United Kingdom):** Instillation of mydriatic for a limited time can result in permanent post-pharmacological dilation avoiding the need for surgical pupilloplasty in children
- P 24 Christopher King (United Kingdom):** Severe congenital bilateral corneal ulceration due to Wolf-Hirschhorn syndrome: a case-report and review of the ophthalmic literature
- P 25 Emília Kiss (Hungary):** Juvenile xanthogranuloma - Case report
- P 26 Ana Sofia Lopes (Portugal):** Persistent pupillary membrane: The challenge of the differential diagnosis of congenital cataract
- P 27 Jorge Meira (Portugal):** Phacoemulsification followed by placement of a toric intraocular lens in a child with bilateral lamellar cataract
- P 28 Pilar Tejada-Palacios (Spain):** Long term results in cystinosis treated with 0,55% cysteamine hydrochloride solution
- P 29 Andrea Szigeti (Hungary):** Ectodermal dysplasia syndrome in childhood
- P 30 Nathalie Voide (Switzerland):** Ocular manifestations in Loeys-Dietz syndrome: a case report

Prematurity, Retinoblastoma, FEVR, OCT-Angiography

- P 31 Cecília Czakó (Hungary):** Assessment of retinal microcirculation damage using OCT angiography in a child with Hodgkin's lymphoma
- P 32 Natalya Fomina (Russia):** Sludge phenomenon in patients with type 1 of Retinopathy of Prematurity
- P 33 Liudmila Kogoleva (Russia):** The role of morphometric parameters of optic nerve head and retina in the diagnosis of congenital glaucoma in premature infants
- P 34 Stefan Langenegger (Canada):** Reproducibility of OCT-Angiography in Children
- P 35 Elvira Saidasheva (Russia):** Breastfeeding: role in the progression of retinopathy of prematurity to the threshold stages
- P 36 Jessica Sergenti (Switzerland):** Insidious late malignant transformation of a retinoma
- P 37 Pilar Tejada-Palacios (Spain):** Cerebellar cognitive syndrome in a preterm child. Case report
- P 38 Pilar Tejada-Palacios (Spain):** Cerebral MRI freesurfer volumetry in preterm children with visual dysfunction
- P 39 Jose Torres-Peña (Spain):** Macular thickness in extreme premature born child
- P 40 Flora Toth (Hungary):** Two cases of congenital blindness caused by exudative vitreoretinopathy



Retina

- P 41** **Maria Csidey (Hungary):** Foveal hypoplasia in aniridia
- P 42** **Sabine Defoort-Dhellemmes (France):** Pigmented paravenous retinochoroidal atrophy in a boy with atypical Inflammatory Bowel phenotype of NCF1 mutation (Chronic Granulomatous Disease)
- P 43** **Lucia Derriman (United Kingdom):** An Interesting Case Of Rod-Cone Dystrophy In a Child
- P 44** **Valeria Gaal (Hungary):** Acute posterior multifocal placoid pigmentary epitheliopathy – case report
- P 45** **Špela Markelj (Slovenia):** Incomplete Vogt-Koyanagi-Harada disease in a 4.5-year-old boy
- P 46** **Lucía Ramos-González (Spain):** Achromatopsia: diagnosis and treatment options. Case report and review of the literature
- P 47** **Ricardo dos Santos Soares (Portugal):** Long chain 3-hydroxyacyl-CoA dehydrogenase (LCHAD) deficiency – a 3-year follow up
- P 48** **Vasily Smirnov (France):** Severe retinitis pigmentosa with posterior pole staphyloma in a family harbouring c.886 A>G RHO mutation
- P 49** **Romain Touzé (France):** Acute macular neuroretinopathy in a young patient with an interferonopathy
- P 50** **Nathalie Voide (Switzerland):** Atypical retro internal limiting membrane hemorrhage in homozygous sickle-cell disease: a case report

Neurofibromatosis, Optic nerve, Uveitis, Trauma

- P 51** **Reem Farwana (United Kingdom):** Optic neuropathy associated with intracranial arteriovenous malformations
- P 52** **Hipólito Fernandes Diogo (Portugal):** Juvenile Idiopathic Arthritis Associated Uveitis – clinical features and complications
- P 53** **Monica Gimeno-Carrero (Spain):** Aggressive recurrent orbital plexiform neurofibroma in a child
- P 54** **Conor Malone (Ireland):** The Luck of the Irish? A case of PKU, NF and ONG
- P 55** **Ana Ortueta-Olartecoechea (Spain):** Resolution of detachment of the neuro-epithelium with dexamethasone intravitreal implant in refractory juvenile idiopathic arthritis-associated uveitis
- P 56** **Gábor László Sándor (Hungary):** Traumatic avulsion of the optic nerve: a case report
- P 57** **Lilla Smeller (Hungary):** Juvenile idiopathic arthritis associated uveitis-when the imaging technology helps the treatment: A case-report
- P 58** **Nicolette Sohar (Hungary):** Sub-tenon triamcinolon acetate treatment in juvenile uveitis
- P 59** **Beata Urban (Poland):** Optical coherence tomography of the anterior segment in children and adolescents with ocular trauma



Poster Abstracts

P 1

Full-length OCT biometry examination of healthy children

Béla Csákány, Flóra Tóth, Mária Csidey, Szilvia Dékány, Emília Kiss, Mária Bausz, Erika Maka

Department of Ophthalmology, Semmelweis University, Budapest, Hungary

Speaker: Béla Csákány

Introduction: The physiologic and refractive-errors-related morphological changes in childhood can be measured with optical biometry. The aim of our study was to survey the new potentials of the full-length optical coherence tomography (OCT) biometry for school-age children.

Methods: Ophthalmologically healthy children with moderate refractive error were selected and optical biometry was performed with Zeiss IOLMaster 700. We recorded the axial length (AL), the anterior chamber depth (ACD) and the lens thickness (LT). Additionally the images of the lenses were compared to adult lens images.

Results: The well-known correlation between age and AL was detected, but there was no correlation between age and ACD or age and LT. The subcapsular lens layer shows difference between childhood and adult cases.

Conclusion: The full-length OCT biometry is a promising method for non-contact detection of the morphological developmental changes and follow-up of refractive errors in childhood. This equipment is suitable for measure the biometric data of school-age children.

P 2

Evaluation of the PlusoptiX Photo screener in the examination of children with Intellectual Disabilities

AbdulRahman Fagih, Lina Raffa, AbdulRahman Al Shamrani, Kareem Allinjawi, Firas Madani, Ali Al Garni

King Abdul Aziz University Hospital, Jeddah, Saudi Arabia

Speaker: AbdulRahman Fagih

Objective: Ocular disorders are frequently observed in children with intellectual disabilities (ID). A photoscreener such as the PlusoptiX may be an effective tool to be used in examining children with ID. The aim of the study was to evaluate the ability of the PlusoptiX vision screener (PVS) to detect amblyogenic risk factors (ARFs) according to the 2013 AAPOS Vision Screening Committee guidelines for automated vision screeners.

Methods: In this cross-sectional study, 44 number of children attending a school for special needs underwent screening with the PVS and complete ophthalmologic examinations. Using ophthalmologic examination as the gold standard, prevalence, sensitivity, specificity, positive predictive value, negative predictive value and testability were calculated.

Results: A total of 44 children with special needs (average age, 8.5 years; range, 4-20 years) were included. The PVS recommended referral of 31/44 children (referral rate 70%). Of these, 39 children (88.6 %) met the referral-positive threshold for strabismus, reduced vision and/or amblyogenic factors on examination by the pediatric ophthalmologist. The plusoptiX had a sensitivity of 40% (CI 7.26%-82.96%), specificity of 78.2% (CI 54.90% -84.54 %), positive predictive value of 15.4% (CI 2.71%-46.34%), and negative predictive value of 90.3% (CI 73.10%-97.47%). The PVS underestimated refractive errors by 0.67 to 0.71 D in right and left eyes respectively ($p < 0.001$ and $p = 0.002$). Testability was relatively low with the PVS at 75% compared to the gold standard examination at 100%.

Conclusion: While Plusoptix might be a useful tool in pediatric vision screening, based on our results, it might not perform as well in children with intellectual disabilities. Use of the PVS as single screening test in young children may miss a significant number of children with amblyopia or amblyogenic risk factors.

Keywords: pediatric vision screening, photoscreening, special needs, strabismus



P 3

Longterm surgical outcomes in children with primary congenital glaucoma

Eirini Kostopoulou¹, Dimitrios Giannoulis¹, Asimina Mataftsi², Nikolas Ziakas¹

¹ 1st Ophthalmology Department, Aristotle University of Thessaloniki, Thessaloniki, Greece

² 2nd Ophthalmology Department, Aristotle University of Thessaloniki, Thessaloniki, Greece

Speaker: Kostopoulou Eirini

Introduction: To assess the long-term effectiveness of surgical treatment in reducing the intraocular pressure (IOP) in children with primary congenital glaucoma (PCG).

Methods: Retrospective study including patients diagnosed with PCG who underwent surgical treatment (goniotomy, trabeculotomy or trabeculectomy) for IOP control, over a period of 11 years (2003-2014). Surgical success was defined as stable IOP of less than 22 mmHg, with or without medication.

Results: Eighteen patients (27 eyes) were included in the study. Nine cases were bilateral. Mean follow-up time was 101.67 months (8.5 years). In 23 eyes (85.2%), the IOP was successfully controlled, with mean reduction of 10.35 mmHg ($p < 0.001$). 15 eyes had fully controlled IOP with surgical procedures only, while 7 eyes needed medication. The post-operative best corrected visual acuity (BCVA) was 5/10 or more in 37% of cases, 1/10 – 4/10 in 22.2% and $< 1/10$ in 29.6%. The cup/disc ratio was stable or improved in 55.6% of eyes. IOP was controlled with one surgery in 11.1% of the eyes, while the majority needed two (48.1%) or three (40.7%) surgeries. There were no intraoperative or early postoperative complications and a single late postoperative complication (phthisis) appeared in one eye.

Conclusion: In the majority of children with PCG, all of the three surgical procedures can achieve an excellent IOP control in the long term. Topical antiglaucoma medication could be helpful in resistant cases.

P 4

Infantile congenital nystagmus and botulinum toxin: a hypothesis to consider?

Ana Sofia Lopes, Susana Henriques, Cristina Vendrell, Mafalda Mota, Sara Pinto, Maria João Santos

Hospital Professor Doutor Fernando Fonseca, Lisboa, Portugal

Speaker: Ana Sofia Lopes

Introduction: Nystagmus is characterized by involuntary, conjugate, horizontal and spasmodic ocular oscillations, representing a failure in the oculomotor control system, and the infantile congenital form begins until 6 months of age. Treatment includes the injection of botulinum toxin type A (BTA) into the horizontal rectus muscles or into the retrobulbar space and the recession or resection of the horizontal rectus muscles. Even in cases with less satisfactory results, the application of BTA has the advantage of assisting in the planning of surgery.

Methods: Presentation of the pre and postoperative evaluation of 3 patients with infantile congenital nystagmus submitted to BTA injection, with good results.

Results: Case 1 – A 4-year-old child with nystagmus with complete alternating block in the levo and dextroversion and with a vicious position of the head, preferentially in dextroversion with the look to the left. After 4 months of BTA injection in the right medial rectus and in the left lateral rectus, he presented orthophoria for near and far, without nystagmus and without a vicious position of the head, which maintains at the 1st year and a half of follow-up. Case 2 – 8-year-old child with nystagmus with blockade position in dextroversion and in the primary position of the look (PPL), with a slight vicious position of the head in levoversion. He underwent TBA injection in the right lateral rectus and in the left medial rectus, which he repeated twice, showing a great improvement of the nystagmus and of the vicious position of the head at the 2nd year and a half of follow-up. Case 3 – A 13-year-old girl, with LE endotropia and nystagmus with a position of blockade in dextroversion and with a vicious position of the head in levoversion. She previously performed BTA injection in both horizontal rectus and also left medial rectus retroinsertion. After the last injection of BTA (in the right lateral rectus and left medial rectus) at 12 years old, she presenting orthophoria in PPL and very significant improvement of the nystagmus and of the vicious position of the head.

Conclusion: Injection of BTA by attenuating the characteristics of nystagmus may allow reduction of nystagmus amplitude and improvement of anomalous posture of head and VA. Despite having a temporary action, in the cases presented was effective, with a relatively long-lasting effect, thus enhancing its importance as a hypothesis to consider in the treatment of this pathology.



Poster Abstracts

P 5

Eye Care Survey in a Special Needs School in Jeddah

Lina Raffa, Mashari AlSheikh, Abdulrahman Al-Shamrani, Firas Madani, Ali AlGarni, Kareem Allinjaw
King Abdulaziz University Hospital, Jeddah, Saudi Arabia

Speaker: Mashari Alsheikh

Introduction: Relatively few data exist on the status of eye care among individuals with intellectual disabilities (ID) in Saudi Arabia. The aim of this study is to assess eye care status among individuals attending a special needs school in Jeddah.

Method: This study was conducted between March and April of 2018 among subjects with ID in the age range of 4.4–34.8 years. A questionnaire was designed to investigate the attitudes of parents toward eye care for their mentally challenged children and possible barriers to accessing eye care for this group. An exploration was undertaken to determine whether these beliefs and barriers are influenced by certain demographic factors. This was a part of a larger cross-sectional study where 46 of these children underwent a complete eye exam.

Result: A total of 50 completed questionnaires were analyzed (81% response rate). Approximately 31.4 % of caregivers believed in the importance of eye exams for children with ID and 29.4% believed that their children suffer from visual impairment, yet 49% reported that their children have never received an eye exam post infancy period. The prevalence of wearing glasses was 3.9%, yet 62.7% of these children were prescribed glasses in our cross-sectional study. Only 29.4% of caregivers sought ophthalmological care within the last 24 months despite having detected ophthalmological abnormalities in 90.9% of these children. Having had a previous eye exam was not significantly associated with average household income, type of health service, parental educational level, parental job status or presence/absence of chronic illnesses. Forty-one % consanguinity was not found to be significantly correlated with positive family history of ocular or neurological diseases. Caregivers' major reasons for not seeking eye care included the belief that their children did not need an eye checkup (35.3%), followed by prioritizing other medical issues (7.8%), transportation barrier / financial burden (2.0%), severe phobia of the child (2.0%), or lack of referral by the treating physician (2.0%).

Conclusion: This study suggests that vision care status among individuals with ID in this special need school is poor. The study provides evidence of parental misconception around the necessity of eye care for this group which should be explored on a larger scale.

P 6

Healthcare Resource Utilization and Costs Associated with Infectious Conjunctivitis: A US Claims Analysis

Sujata Sarda¹, Wendy Cheng², Nora McCormick², Duh Mei Sheng², Corey Joseph¹, Jay Pepose³

¹ Shire, Lexington, MA, USA

² Analysis Group, Inc. Boston, MA, USA

³ Pepose Vision Institute, Chesterfield, MO, USA

Speaker: Sujata Sarda

Introduction: Conjunctivitis is a common condition that affects six million people in the US annually, including 1 in 8 children. It can also affect family members ("caregivers") who may have to miss work to care for patients. Healthcare resource utilization (HRU), direct medical costs (DC), and caregiver work-loss costs have been analyzed to assess the impact of this widespread condition on patients and their families.

Methods: In Optum Healthcare Solutions data (1998–2016), patients with ≥ 1 conjunctivitis diagnosis (cases) or without (controls) were identified. All-cause DC and caregiver costs from 60 days post-conjunctivitis diagnosis (for cases) or an imputed date (for controls) were compared using cost differences in linear regressions. HRU incidence rates were reported on a per-person-per-month (PPPM) basis. Incidence rate ratios (IRR) comparing HRU of cases to controls and 95% confidence intervals (CI) were calculated with a Poisson distribution. Costs incurred from a caregiver's missed time from work were imputed based on the patient's HRU and the caregiver's wage data (if available). A weekday emergency room (ER) visit equaled 1 day missed from work, while an outpatient or other visit equaled a half day missed from work. Inverse probability weighting was used to adjust for baseline differences between all cases and controls, and between cases and controls whose caregivers had wage data.

Results: After weighting, baseline differences were well balanced between all cases ($n=1,002,188$) and controls ($n=4,877,210$) and between cases ($n=499,432$ [49.8%]) and controls ($n=1,828,359$ [37.5%]) with caregiver wage data. HRU and costs were higher for cases than controls. Cases had 1.67 all-cause visits PPPM vs 0.79 for controls for an IRR of 2.12 [95% CI: 2.12–2.13]. The ER visit IRR was 3.10 [3.08–3.13] and the outpatient visit IRR was 2.18 [2.17–2.18]. Total direct costs were \$106.42 [\$104.60–\$108.31] PPPM higher, ER costs were \$15.89 [\$15.63–\$16.14] PPPM higher, and outpatient costs were \$63.78 [\$62.85–\$64.78] PPPM higher, for cases than controls. Case caregivers missed a mean (SD) of 0.66 (0.75) work days PPPM vs 0.29 (0.66) for control caregivers ($p<0.0001$). Case caregivers also incurred \$126.22 [\$125.25–\$127.16] higher work loss costs PPPM than control caregivers.

Conclusion: Increased HRU associated with conjunctivitis translates to greater patient and familial economic burden. Treatments that reduce the costs and transmission of conjunctivitis are needed.



P 7

Pediatric examination under anesthesia – What's the value?

Filipa Teixeira, Filipa Caiado, Raquel Marques, Filomena Pinto, Eduardo Silva, Fátima Campos
Hospital Santa Maria, Lisboa, Portugal

Speaker: Filipa Teixeira

Introduction: In some cases of uncooperative children a complete ocular examination cannot be performed. Examination under anesthesia (EUA) often has to be resorted to eliciting accurate diagnosis and management in these cases. Few data are available on the clinical impact of the EUA. This study was conducted to evaluate the contribution of ophthalmic EUA for the management of children with ophthalmic disorders, using the Greenwich Grading System (GGS).

Methods: Retrospective analysis of pediatric patients who underwent EUA over a 10-year period. Data captured from the medical records included patient's bio-data, past medical history, motive for referral, ophthalmic examination and complementary diagnostic tests. The GGS was used to quantify the contribution of EUA for the diagnosis, overall investigation and treatment of each patient.

Results: A total of 190 medical records were reviewed, 30 were excluded. Mean age was 37 ± 33 months. Most referrals were requested for investigation of nystagmus (24,4%), suspicion of retinal dystrophy (16,3%) and unexplained decreased visual acuity (15,0%). Analysis of the EUA results with the GGS demonstrated an important clinical impact of this examination. Based on the EUA findings a new diagnosis was made in 29,4% and a diagnosis was confirmed or excluded in 61,3% of the cases. Regarding therapeutic management, the EUA allowed reassurance and explanation of the disease in 55,0% to children and their parents, and in 35,6% of the cases a new treatment was initiated based on the results of this exam.

Conclusion: EUA is a valuable investigation for the management of pediatric patients. In most cases, the EUA has an important clinical impact by confirming or excluding a diagnosis and also by allowing explanation and reassurance to children and parents.

P 8

Baerveldt Attached to XEN: A New Technique for Secondary Paediatric Glaucoma

Filipa Teixeira¹, Filipa Caiado¹, Inês Leal¹, Eduardo Silva², Luis Abegão-Pinto¹

¹ Hospital Santa Maria, Lisboa, Portugal

² Hospital Lusíadas, Lisboa, Portugal

Speaker: Filipa Teixeira

Introduction: The Baerveldt Glaucoma Implant (BGI) is a drainage device often used in cases of secondary paediatric glaucoma. However, this device is both associated with early hypotony-related complications and late corneal decompensation. Using the BGI in combination with the XEN gel stent as a flow restrictor device in the anterior chamber has been suggested to optimize BGI aqueous outflow control while minimizing long term corneal trauma. We describe the surgical outcomes this novel combined procedure in paediatric glaucoma.

Methods: Retrospective case series of 2 patients (3 eyes) that underwent combined implantation of BGI with XEN gel stent. Surgical indication, number of medications and intraocular pressures (IOP) and intra-operative findings were retrieved from medical records. Safety outcomes such as visual acuity or need to re-intervention was additionally noted. Absolute Surgical success was defined as an IOP < 21 mmHg with a minimum of 30% decrease from baseline. Resorting to medication to achieve previous parameters accounted for relative success.

Results: Case 1 was a female patient of 8 years-old with congenital bilateral aniridia with uncontrolled IOP despite quadruple medical therapy (IOP right eye (RE) 36 mmHg and left eye (LE) 40 mmHg) with no previous surgery. Uneventful BGI-XEN implantation was performed on both eyes and at last follow-up visit, IOP was 14 mmHg in both eyes with no medical therapy. Case 2 relates to a 14 years-old female patient with uveitic glaucoma, previous history of evisceration of the LE and in the RE five failed previous glaucoma surgeries, including 3 Ahmed Valve extrusions and diode laser. Prior to this procedure, IOP was 34 mmHg and at last follow-up, IOP was 20 mmHg. There were no cases of hypotony, ocular motility disorders or decrease in baseline visual acuity. With a mean follow-up time of 2.7 months, all 3 BGI-Xen implants amounted to absolute success, with good IOP control no need to re-intervention.

Conclusion: Combining BGI with Xen gel stent potentially to be a safe and efficient procedure in paediatric population with secondary glaucoma's. Larger series with longer follow-up times are needed to validate our findings and establish the place of this novel procedure in the paediatric glaucoma algorithm.



Poster Abstracts

P 9

Roll of the optical coherence tomography in the diagnosis of leukoencephalopathy associated with mutation in POLR1C

Jose Torres-Peña, Pilar Tejada-Palacios, Ana Ortueta-Olartecoechea, Monica Gimeno-Carrero, Ana Martinez-de-Aragon, Ana Camacho-Salas
Hospital Universitario 12 de Octubre, Madrid, Spain

Speaker: Jose Torres-Peña

Introduction: Leukoencephalopathy are a heterogeneous group of genetically determined disorders characterized by abnormal white matter on brain imaging.

The recessive mutations in POLR1C, a gene encoding a shared POLR1 and POLR3 subunit, also mutated in some Treacher Collins syndrome, could cause leukoencephalopathy in some patients.

Methods: 8-year-old patient, referred to our practice for low visual acuity. In the exploration we found better corrected visual acuity in both eyes of 0.2. In the fundus of the eye, a papillary asymmetry with pale papilla of the right eye was seen. We found thinning in the ganglion cell layer of the retina and in the nerve fiber layer of the retina. The mother tells us that her daughter has difficulties to interact and is clumsy.

Results: The magnetic resonance image showed diffuse hypomyelination and thinning of the corpus callosum. The diagnosis was confirmed with the genetic result of gene alteration POLR1C.

Conclusion: The study of ganglion cells of the retina was useful to identify a disease of white matter in this patient. This test was the key to start with the correct management of this patient.

P 10

Case report: Conventional and new imaging techniques of fovea plana in children

Tamás Zeffer, Eszter Vizvári, Ágnes Jánossy, Edit Tóth-Molnár
University of Szeged, Department of Ophthalmology, Szeged, Hungary

Speaker: Tamás Zeffer

Introduction: We report a case of a 7-year-old boy with fovea plana.

Methods: Detailed ophthalmological examinations, including electrophysiological investigations, fundus photography, optical coherence tomography (OCT) and OCT angiography were performed in a 7-year-old child.

Results: His best corrected visual acuity was 20/25 on his right eye and 20/28 on his left eye. Anterior segment examinations disclosed any pathological alterations. Fundus examination revealed the absence of foveolar reflex in both eyes. OCT examination was performed which showed no foveolar depression. OCT angiography was also performed which could exhibit the absence of the foveolar avascular zone either in the superficial and the deep retinal layers. Although visual evoked potentials (VEP) were within normal limits with 60' stimuli, the results were subnormal with 15' stimuli. Pattern electroretinography (PERG) proved to be subnormal in both eyes suggesting the deterioration of the macular functions.

Conclusion: Our findings further support the notion, that new diagnostic methodologies, such as OCT and OCT angiography provide essential additional insights into the morphological alterations of the macular region in fovea plana. Detailed explorations and follow-up of the macular structure can improve our knowledge about the disease evolution.



P 11

A case of congenital lacrymal gland agenesis in a patient presenting BPES syndrome

Martina Delle Fave, Jacques Lasudry, Monique Cordonnier

Université Libre de Bruxelles, Hôpital Erasme, Bruxelles, Belgium

Speaker: Delle Fave Martina

Introduction: BPES is an autosomal dominant syndrome characterized by the presence of blepharophimosis, epicanthus inversus and ptosis. Sporadic mutations have been reported. Mutation occurs in FOX L2 gene. BPES type 1 is characterized by the association with primary ovarian failure, type 2 presents with ophthalmic features only. Congenital lacrymal gland agenesis has been reported in a restricted number of BPES patients. There is no guidelines for management and treatment of this condition.

Aim: To illustrate a case of BPES in a child presenting signs and symptoms of congenital lacrymal gland agenesis and its management.

Case: A 2-y old girl with BPES and FOX L2 mutation was referred to our University Hospital for ptosis surgery. She presented with BPES features, visual acuity was impossible to measure, severe photophobia was noticed. The parents reported absence of tears when she was crying. Examination during general anesthesia was carried out showing high bilateral hyperopia (+8), normal corneal diameter (12mm), severe bilateral filamentous keratopathy associated with punctate superficial keratitis, patent lacrymal ways, IOP 12 mm (Perkins tonometer) and unremarkable fundus bilaterally. MRI was prescribed to assess for lacrymal glands and showed lacrymal gland agenesis. Four punctum plugs were inserted, ointment and intense lubrication was prescribed as well as lid hygiene. After four months of follow up, the 4 plugs were in place. Corneal aspect was much improved on both sides and photophobia was less invalidating.

Conclusion: We illustrate a case of lacrymal gland agenesis in BPES and how we managed its consequences of severe photophobia and keratopathy. The presence of photophobia and dry eyes in BPES should alert the clinician and lead him to check for the presence of lacrymal glands. Punctum plug were a valid choice to manage decreased tear production in this case. Intense lubrication, and hygiene are mandatory.

P 12

Outcome in congenital ptosis surgery

Fabienne Fierz, Karla Chaloupka, Marvin Marti, Christina Gerth-Kahlert

Department of Ophthalmology, University Hospital Zurich, Zurich, Switzerland

Speaker: Fierz Fabienne

Background: The main objective for ptosis surgery in childhood is to enable and improve visual development and reduce associated anomalous head posture. We present the outcome after uni- or bilateral ptosis surgery in children at our institution.

Methods: Clinical data including type of surgery, pre- and postoperative findings, postoperative complications and re-operation rate were collected retrospectively from medical notes of all paediatric patients undergoing ptosis surgery from 2006-2017. The study was approved by the local ethics committee.

Results: 21 children were included in the study undergoing uni- (n=11) or bilateral (n=10) ptosis surgery at a mean age of 3.2 years (range, 3 months to 10 years) with the diagnosis of blepharophimosis, ptosis and epicanthus inversus syndrome (BPES): 4, congenital ptosis associated with significant systemic comorbidity/ malformation: 8, and isolated ptosis: 9 children. Surgical techniques included frontalis suspension with silicone/ prolene or fascia lata, levator resection and Mullerectomy. In all cases, the operation led to improvement of lid opening, of visual behavior and/ or reduction of anomalous head posture. Uniocular visual acuity at last follow up was available in 17 patients and was equal or with an inter-ocular difference of less than one line on the decimal scale in 16/17. A majority of patients received occlusion therapy for amblyopia treatment. Postoperative wound infection of either implant material or skin donor site was reported in 3, incomplete lid closure in 15 and mild or severe keratopathy in 3 cases. Recurrence requiring repeat surgery occurred in 3 patients during the mean follow-up period of 15.5 months (range; 3-157 months).

Conclusion: Ptosis surgery leads to major functional benefit in affected children. Visual outcome after surgical correction and amblyopia treatment was excellent in our cohort. Incomplete lid closure was a commonly reported postoperative finding and can generally be managed with lubrication, whereas only one patient developed visually significant keratopathy. As demonstrated by our data, implantation of foreign material might be prone to infections. After the age of two, autologous fascia lata suspension is therefore the preferred option in most cases.



Poster Abstracts

P 13

Management of Lacrimal Alterations in A Child with Fraser Syndrome

Monica Gimeno-Carrero, Ana Barceló-Mendiguchia, Pilar Tejada-Palacios, Ana Romance, Ana Maria Dorado Lopez-Rosado, Alicia Muñoz-Gallego

Hospital Universitario 12 de Octubre, Madrid, Spain

Speaker: Monica Gimeno Carrero

Introduction: Fraser syndrome is a rare autosomal recessive disorder which includes cryptophthalmos, syndactyly, genitourinary tract abnormalities, craniofacial dysmorphism, laryngeal anomalies, malformations of the ear and nose and musculoskeletal defects. FRAS1, FREM2 and GRIP 1 genes have been linked to this syndrome. Around 200 case reports of patients with Fraser syndrome and cryptophthalmos have been published.

Methods: We describe the case of a 7-year-old male with complete right unilateral cryptophthalmos associated with right microphthalmia. He presented the complete variety of this syndrome that consist on the absence of eyelids with skin growing continuously from the forehead to the cheek. In addition, this patient presented other systemic anomalies: right renal agenesis, right temporal and parietal bone agenesis and lateral and inferior orbital walls defects. In contrast, he had a correct psychomotor development. Various interventions were performed with fronto-orbital distractors and cranioplasty with rib and calvarial graft. Our patient complained of severe epiphora of the left eye as well as recurrent dacryocystitis in the right eye that caused significant swelling and pain.

Results: Two unsuccessful lacrimal probings were made in his left eye. A dacryocystography was performed because of the nasal bone alterations and finally a successful left lacrimal intubation could be done. Surgical right dacryocystectomy was made by a multidisciplinary approach which included ophthalmology and maxillofacial service, as the patient complained of great pain because of repetitive dacryocystitis episodes.

Conclusion: Despite the absence of the right eye, the main complaint of the patient was the constant discomfort due to the epiphora of the normal eye. Moreover, the continuous episodes of dacryocystitis of his right lacrimal sac caused a detriment of his life quality. Therefore, the resolution of these minor problems have caused a significant improvement in the patient's situation.

P 14

Division of lid adhesions in a case of Ankyloblepharon-Ectodermal Defects-Cleft Lip syndrome

Pablo Nadal Iglesias, Daniel Jackson, Goran Darius Hildebrand

Oxford University Hospitals NHS Trust, Oxford, United Kingdom

Speaker: Daniel Jackson

Introduction: Ankyloblepharon filiforme adnatum (AFA) is a rare congenital abnormality in which single or multiple bands of tissue fuse the upper and lower eyelids together. AFA can be associated with other ocular abnormalities and numerous underlying syndromes. We describe a case of Ankyloblepharon-Ectodermal Defects-Cleft Lip (AEC) syndrome in a newborn and the procedure used to divide the lid adhesions. We emphasise the need for a multidisciplinary approach in the investigation of associated systemic disease, and the need for prompt treatment to prevent amblyopia.

Methods: Single case report of a neonate born with AEC syndrome at our institution (Oxford University Hospitals NHS Trust, UK). Clinical features of the condition are discussed and details of surgical intervention to divide the ankyloblepharon are explained.

Results: A baby was born at 39 weeks by emergency caesarean section due to abnormal cardiotocograph. Antenatally he had been diagnosed with a cleft lip and palate. At birth he was noted to have severe peeling of his skin, requiring admission to a high dependency unit for 2 hourly emollient application. He was also noted to have partially fused eyelids, abnormality in the shape of his ears and hypertelorism. A clinical diagnosis of AEC syndrome was made and genetic testing was performed.

Division of the eyelids was performed at the bedside in neonatal ICU under topical anaesthesia. The lids were lifted up from the underlying cornea, for example, by placing two lacrimal probes under the ankyloblepharon, and to put the ankyloblepharon under tension. Vannas scissors were used to divide the adhesions. Minimal bleeding was encountered which ceased with gentle pressure. Hand-held cautery was on standby but not required. The procedure caused no noticeable distress to the neonate. The baby was able to fully open both eyelids immediately. The remaining ophthalmic examination was normal. Review 1 week post-procedure showed full, spontaneous lid opening bilaterally, with no visible scarring or other lid abnormality.

Conclusion: Congenital AFA can be a feature of several underlying genetic conditions with systemic sequelae. Detailed investigation using a multi-disciplinary approach is required. We describe a simple procedure to divide the lid adhesions using minimal equipment, easily performed at the bedside and causing minimal distress to the neonate. We propose this should be performed at the earliest opportunity to prevent amblyopia.



P 15

Craniosynostosis in Alagille syndrome: A case series and review of the literature

Christopher King, Göran Darius Hildebrand
Oxford University Hospitals NHS Foundation Trust,
Oxford, United Kingdom

Speaker: Christopher King

Introduction: Alagille syndrome is a rare genetic disorder associated with multi-system abnormalities in the liver, heart, skeleton, eyes and face. It is dominantly inherited and caused by loss of function mutations in JAG1 or NOTCH2. Seventy-six percent of patients with Alagille syndrome are found to have optic disc abnormalities which are often attributed to disc drusen or anomalies of their syndrome. To date there are three published cases of patients with Alagille syndrome and craniosynostosis. In addition to those patients with craniosynostosis, there are two further case reports of patients with Alagille syndrome and papilloedema secondary to idiopathic intracranial hypertension.

Method: Case series and review of the literature

Results: We present three further children with genetically confirmed Alagille syndrome found to have craniosynostosis. All three children had papilloedema due to unrecognized severe intracranial hypertension and underwent urgent cranial vault expansion surgery. One child irreversibly lost all vision despite all interventions due to delayed presentation.

Conclusion: Our case series highlights the need for close monitoring of patients with Alagille syndrome and abnormal optic discs and a low threshold to look for any associated craniosynostosis and to consider neuroimaging and CSF pressure measurement.

P 16

Encephalocraniocutaneous lipomatosis (diagnosis, differential diagnosis, treatment, follow up)

Olga Lukáts, Erika Maka, Zoltán Nagy
Semmelweis University, Department of Ophthalmology, Budapest, Hungary

Speaker: Olga Lukáts

Aim: To show our three patients with encephalocraniocutaneous lipomatosis. To discuss characteristic signs of the disease and the differential diagnostic possibilities.

Material, method: Our three patients with encephalocraniocutaneous lipomatosis (two boys age of three and six and a girl age of five) show characteristic signs of the disease – CNS lipomatosis, eyelid and ocular surface choristomas, eyelid connective tissue nevi, alopecia, lack of a part of brain. Operation was made in two patients – removing eyelid nevi and ocular surface choristomas. Purpose of the operation was social rehabilitation for request of the parents.

Summary: Encephalocraniocutaneous lipomatosis is rare congenital disorder. It has unknown origin. Life long multi-disciplinary follow up of the patients is necessary (ophthalmologist, dermatologist, neurologist, neurosurgeon, plastic surgeon, paediatrician).





Poster Abstracts

P 17

Clinical features and surgical treatment for progressive bilateral ptosis in Kearns-Sayre syndrome: a case report

Otto Alexander Maneschg¹, Andrea Szigeti¹, Petra Zsidegh², Zoltán Zsolt Nagy¹, Erika Maka¹

¹ Department of Ophthalmology, Semmelweis University, Budapest, Hungary

² 1st Department of Paediatrics, Semmelweis University, Budapest, Hungary

Speaker: Maneschg Otto Alexander

Introduction: Kearns-Sayre syndrome (KSS) is a mitochondrial disease with a typical onset before 20 years of age. It is described as a subtype of chronic progressive external ophthalmoplegia (CPEO).

Case report: We report a case of a 3 years old girl with progressive bilateral ptosis, absence of Bell's phenomenon, weakness of horizontal ductions, abnormal head posture (AHP), facial abnormalities, hyperpigmentation on peripheral retina and proximal muscle weakness. Cranial MRI showed slight pontin, cerebellar and corpus callosum atrophy and delayed myelinisation. Frontal suspension on both eyes and muscle biopsy for genetic analysis were performed under general anaesthesia. Muscle biopsy characteristically showed ragged red fibers, which substantiate the Kearns-Sayre syndrome diagnosis. During follow up of 12 months we did not found progression of ptosis, AHP normalized and strabismus surgery was not necessary till now.

Conclusion: Early performed surgical treatment against ptosis and strabismus may avoid amblyopia, special supplementation with vitamins, cofactors and regular exercise may also improve quality of live. Interdisciplinary management is fundamental for exact diagnosis and treatment of this rare disease.

P 18

Treatment of congenital nasolacrimal duct obstruction in children by monocanalicular intubation with a lacrimal duct stent

Iren Szalai, Otto Alexander Maneschg, Dorottya Krisko, Zoltan Zsolt Nagy
Department of Ophthalmology, Semmelweis University, Budapest


Speaker: Iren Szalai

Introduction: Obstruction and stenosis of lacrimal pathways are the most common causes of epiphora in early childhood. In most cases spontaneous resolution occurs by 1 year of age. In this retrospective analysis we evaluate the clinical outcomes after intubation with a lacrimal duct stent (Masterka®, FCI Ophthalmics) in persistent congenital nasolacrimal duct obstruction (CNLDO).

Methods: Between January 2015 and June 2018 we treated 9 patients (2 female, 7 male) with an average age of 4.1 years (± 1.8). Indication for this treatment was a congenital nasolacrimal duct obstruction not solved by probing. Patients with associated canalicular congenital punctal disorders, eyelid malposition, and less than 6 month-long history of tearing were excluded. Implantation of Masterka® stent was performed under general anesthesia.

Results: Epiphora was the most common presentation, followed by pus secretion and chronic inflammation of the eyelids and conjunctiva. Involvement of both eyes was noted in 2 cases. We did not found other abnormal clinical findings, mean refraction power error of spherical equivalent was $+ 1.25 (\pm 1.50)$, measured in cycloplegia before treatment. Masterka® stent was removed after an average of 4.7 months (± 5.2), treatment time was without complications, and relapse effects were not noted after a mean follow up time of 12 months.

Conclusion: The Masterka® stent implantation is minimally invasive, easy to perform, can be useful in a younger patient with congenital NLDO and has a high success rate.



P 19

Digital images of the fundus under inferior oblique weakening surgery

Alexandr Tereshchenko, Irina Trifanenkova, Aleksandra Vydrina

Kaluga branch of FGau «NMIC «MNTK «Eye Microsurgery» named after acad. S.N. Fedorov», Kaluga, Russia

Speaker: Vydrina Aleksandra

Introduction: inferior oblique overaction (IOOA) is the most common cause of isolated vertical deviation. Surgical treatment of IOOA can be accomplished by inferior oblique (IO) weakening procedures. Many IOOA patients have ocular extorsion and fusional cyclovergence. Ocular torsion angle measurement allows to estimate the efficiency of surgical treatment in patients with IOOA and can be measured both subjectively and objectively. We used digital images of the fundus to measure ocular torsion angles in patients with IOOA pre- and postoperative.

Methods: 60 children with vertical strabismus. Group 1 consisted of 26 children (42 eyes), where the vertical deviation did not exceed 7 ° by Hirschberg test (3-7°; 6,05±1,25°); preoperative vertical deviation in the primary gaze was present in only 13 patients (4,67±1,37°). The preoperative excyclotorsion averaged 16, 21±2,02 degrees. Group 2 consisted of 34 children (54 eyes) with a vertical deviation of more than 7 (8-25°; 15,37±4,85°); 16 patients had a hypertropia in the primary gaze (8,77±2,58°). The preoperative excyclotorsion averaged 18,96±2,57 degrees. All patients underwent of dosage anterior transposition of the inferior oblique. In the first group, during surgery, the inferior oblique muscles were sutured to the sclera 2 mm below the level of attachment of the inferior rectus muscle. In the second, at the same level with it.

Results: In Group 1, vertical strabismus was completely removed by surgery in the primary gaze in 17 eyes (94,4%); overelevation in adduction of the eye - in 40 eyes (95,2%). In Group 2, vertical strabismus was completely removed by surgery in the primary gaze in 20 eyes (90,9%); overelevation in adduction of the eye - in 54 eyes (94,4%). After surgery, mean torsional angle significantly decreased in all patients in two group. The decrease in excyclotorsion was 6,17±1,96 degrees in group 1 and 7,3±1,67 degrees in group 2. The values of cyclodeviations after the operation were stable throughout the observation period.

Conclusion: Our proposed method of correcting degree anterior transposition of the inferior oblique muscle is an effective method for the surgical correction of vertical strabismus (94% of the vertical deviation can be completely eliminated). It reduces the number of surgical steps in the treatment of vertical strabismus.

P 20

Eyelid Reconstruction in Barber-Say Syndrome

Carla Villena, Antonio Barreiro, Paula López, Lucía Ramos, Montse Évole, Honorio Barranco

Hospital Universitario y Politécnico La Fe, Valencia, Spain

Speaker: Carla Villena

Introduction: Barber-Say syndrome is an unusual ectodermal dysplasia caused by the mutation of the TWIST2 gene (2q37.3), which encodes a protein that acts at an epigenetic level. We present the case of a 2-day-old male in whom ectropion, hypertelorism, hypertrichosis and other dysmorphic features led to the clinical diagnosis of Barber-Say syndrome, afterwards confirmed with genetic test.

Methods: A 2-day-old male was born at term by caesarean delivery and pregnancy was uncomplicated. On ophthalmic examination, hypertelorism and congenital eversion of the four eyelids was observed, exposing the tarsal conjunctiva when the baby cried. Of note on general examination, his nasal root was broad and had dysplastic and low set ears. Moreover, the patient presented retrognathia, long philtrum, wide mouth with thin lips, hypertrichosis, and hypoplastic nipples. Left testis was lodged in the inguinal canal. Our surgical approach included a temporary tarsorrhaphy and full-thickness skin grafts taken from the ventral side of the forearm, retroauricular area and from the supraclavicular fossa, as well as autologous lipografts from the inner side of both thighs for palpebral reconstruction.

Results: No complications after the surgery have been related to the grafts and the case progresses aesthetic and functional favorably, so the child is now able to fully close the eyes and no epiphora or eyelid rigidity are registered.

Conclusion: Since the publication of the first case, of Barber-Say Syndrome in 1982, fewer than 20 cases have been described so the surgical approach was a reconstructive challenge owing to both its size and the fact that the reconstructive techniques are not well-known. Moreover, any delay in reconstruction would have healed corneal surface avoiding a correct development of visual acuity, besides the psychological impact of a disfiguring syndrome.



Poster Abstracts

P 21

Imaging in Axenfeld-Rieger Syndrome

Mária Bausz¹, Erika Maka¹, Mária Csidey¹,
Zoltán Zsolt Nagy¹, Péter Kivovivcs², Virág Pörzse²

¹ Department of Ophthalmology, Semmelweis University, Budapest, Hungary

² Department of Community, Semmelweis University, Budapest, Hungary

Speaker: Mária Bausz

Introduction: Axenfeld-Rieger syndrome is a rare autosomal dominant genetic condition with anterior segment dysgenesis and systemic abnormalities. The incidence is 1:200,000 worldwide. The ocular manifestation includes posterior embryotoxon, iris abnormalities: hypoplasia, corectopia, polycoria. The developmental anomalies of anterior angle cause glaucoma. Regardless of the etiology, glaucoma can be developed even in early childhood. Besides ocular abnormalities, others, dental and facial bone defects like maxillary hypoplasia, hypodontia, oligodontia and microdontia also can be found. Failure of involution of the periumbilical skin also part of the syndrome. The pituitary involvement also is known in Rieger syndrome. The disorder has an autosomal dominant inheritance with marked clinical and genetical heterogeneity 4q25 (PITX2), 6p25 (FOXC1), 13q14 (RIEG2). Mutations in the genes can cause variation of the phenotype.

Methods: Normally we investigate the anterior segment with a slit lamp or surgical microscope and the angle with gonioscope. The IOP measure with Tonopen or Icare tonometer.

Besides, in case of Axenfeld-Rieger syndrome angle status can be evaluated by RetCam camera, maxilla hypoplasia and dental status were investigated with x-ray or CT scan. Excluding the empty sella and para sellar arachnoidal cysts of the brain, MRI is needed. In cases of elevation of IOP antiglaucoma surgery is needed almost every case (trabeculectomy, or tube surgery).

Conclusion: The diagnosis and the treatment of Axenfeld-Rieger syndrome requires a multidisciplinary cooperation. In case of polycoria and definitely small pupil, the surgical solution should be carried out to avoid amblyopia. In case of secondary glaucoma filtration or tube surgery is suggested. Special dental care and surgeries are also needed in cases of dental abnormalities.

P 22

New PEX11B mutation in 3 siblings with bilateral congenital cataract

Claire Hartnett, Richard Scott,
Ian Christopher Lloyd

Great Ormond Street Hospital, London, United Kingdom

Speaker: Claire Hartnett

Introduction: Peroxisomes are organelles present in almost all cells and play important roles in many metabolic pathways. Peroxisomal membrane protein 11b is a protein encoded by the PEX11B gene. Mutations in PEX11B gene has recently been associated with bilateral congenital cataracts. We describe a new PEX11B mutation and its associated phenotype in 3 patients.

Methods: Three siblings, all previously diagnosed with bilateral congenital cataracts, hypotonia and reduced head circumference, underwent genome wide array analysis. Biochemical analysis of each patient was also performed.

Results: Genome analysis indicated copy number changes at chromosome 1q21.1. Sequence analysis of the PEX11B gene identified the hemizygous mutation c.277_303del (p.Arg93_Asn101del). This mutation was identified in all three patients and confirmed the diagnosis of PEX11B deficiency.

Conclusion: This mutation has not been previously reported. Biochemical investigations are often found to be normal in children with PEX11B deficiency. Our results highlight a different phenotype to previously reported cases and reiterate the importance and clinical utility of genetic testing of children with bilateral congenital cataract.



P 23

Instillation of mydriatic for a limited time can result in permanent post-pharmacological dilation avoiding the need for surgical pupilloplasty in children

Daniel Jackson, Goran Darius Hildebrand

Oxford University Hospitals NHS Trust, Oxford, United Kingdom

Speaker: Daniel Jackson

Introduction: Ectopic, colobomatous or post-traumatic pupils can occlude the visual axis and result in vision loss and amblyopia in children. Long-term mydriatic drops can be an option to avoid surgery, but implementing a regime in children may be difficult. We report an interesting case of permanent pupil dilation after a short course of mydriatic therapy for a slit-like pupil allowing for normal visual development.

Methods: Report of a single case of a child seen and treated at a tertiary referral centre (Oxford University Hospitals NHS Trust, UK). A newborn child, under investigation for Axenfeld-Rieger syndrome, had bilateral irregular congenital pupil abnormalities initially treated with cyclopentolate 0.5% drops twice per day (6am and 1pm) into both eyes for a period of 2 years (25th May 2016 to 24th April 2018). Glasses were fitted to correct for refractive error and cycloplegia. We report the anatomical, clinical and visual outcomes of the case.

Result: The left pupil had extreme corectopia and the right had a slit-like appearance prior to treatment. Both pupils occluded the visual axis. Instillation of the drop regime resulted in adequate dilation to clear the visual axis centrally. The parents had increasing difficulty instilling the drops as the child became older. On review two weeks after cessation of drops, the left pupil had returned to the original shape and therefore vitrector pupilloplasty was performed to prevent amblyopia. The right pupil remained permanently dilated, clear of the visual axis, therefore avoiding the need for surgery. Visual acuity (logMAR) post drops was 0.2 in the right eye and 0.4 in the left eye.

Conclusion: We report an interesting phenomenon whereby mydriatic treatment results in permanent structural change in a pupil, allowing for normal visual development without the need for surgery. We propose a short course of cyclopentolate 0.5% drops twice per day could be trialled before consideration of surgery in cases of corectopia, especially if associated with iris atrophy like in this case of Axenfeld Rieger syndrome.

P 24

Severe congenital bilateral corneal ulceration due to Wolf-Hirschhorn syndrome: a case-report and review of the ophthalmic literature

Christopher King¹, Peter Michael Mota², Göran Darius Hildebrand¹

¹ Oxford University Hospitals NHS Foundation Trust

² East Kent Hospital University NHS Foundation Trust

Speaker: Christopher King

Introduction: Wolf-Hirschhorn syndrome (WHS) is a rare chromosomal abnormality caused by partial deletion of the short arm of chromosome 4. The main clinical features of WHS include growth retardation, seizures, craniofacial anomalies, microcephaly, ocular abnormalities, sensorineural hearing loss, cardiac anomalies and renal abnormalities. Ophthalmic manifestations are present in approximately 30% of cases.

Method: Case report and review of the ophthalmic literature.

Results: We report a newborn baby boy with genetically confirmed WHS, referred with severe bilateral corneal ulceration a few days after birth. The infant was managed with emergency central and lateral tarsorrhaphies and permanent lower punctual occlusion, resulting in successful healing and no recurrence over 18 months of follow-up. A review of the known ophthalmic manifestations was undertaken to identify all known ophthalmic findings in WHS. Alongside several previously described ophthalmic features of WHS, our case demonstrates absent eyelashes which, to the best of our knowledge, has not been previously described.

Conclusion: WHS may present with severe bilateral corneal ulcerations shortly after birth requiring urgent medical and surgical management. Ophthalmic features and techniques for the successful treatment of the severe congenital ulcers and prevention of recurrences over an extended period of time are described.



Poster Abstracts

P 25

Juvenile xanthogranuloma - Case report

Emília Kiss¹, Andrea Szigeti², Zsuzsanna Szalai²,
Mónika Csóka³, Zoltán Zsolt Nagy¹, Erika Maka¹

¹ Department of Ophthalmology, Semmelweis University, Budapest, Hungary

² Department of Dermatology, Pál Heim Children's Hospital, Budapest, Hungary

³ 2nd Department of Pediatrics, Semmelweis University, Budapest, Hungary

Speaker: Emília Kiss

Introduction: Juvenile xanthogranuloma (JXG) is an uncommon benign disease, which is a member of non-Langerhans cell group of histiocytotic proliferative disorders. Most often it has a skin manifestation but they may affect extracutaneous tissues as ocular structures.

Methods: Case report

A 15-years-old boy presented with multiplex conjunctival yellow lesions on both eyes and multiple papulonodular lesions on his face. A large limbal lesion was observed on the right eye. Juvenile xanthogranuloma was confirmed by skin biopsy and histopathological examination. Magnetic resonance imaging revealed lesions in the pharynx and in the thoracic 12 vertebra. The boy was treated with prednisolon and vinblastin according to the LCH-III protocol. Subconjunctival triamcinolone was applied to the right side. Regression was not achieved. Higher intraocular pressure was measured. After the protocol change he got methotrexat, etoposide, vinblastin and cladribine. Significant regression was observed. The conjunctival and corneal lesion on his right eye has been flattened. The lesions of the left eye has been disappeared. 7 months after the last therapy the control MRI showed no abnormal lesions.

Conclusion: JXG may occur on extracutaneous areas. By this case report we would like to draw the attention to this rare disease and the diagnose and treatment highlighting the importance of working with affiliates.

P 26

Persistent pupillary membrane: The challenge of the differential diagnosis of congenital cataract

Ana Sofia Lopes, Susana Henriques,
Cristina Vendrell, Mafalda Mota, Sara Pinto,
Isabel Prieto

Hospital Professor Doutor Fernando Fonseca,
Lisboa, Portugal

Speaker: Ana Sofia Lopes

Introduction: Persistent pupillary membrane (PPM) is a congenital iris anomaly that results from the incomplete involution of the anterior vastis vasculosa causing persistence of the remaining tissue on the pupillary hole. It ranges from fine fibers to dense and extensive membranes that can completely occlude the pupil and cause prelenticular leukocoria and stimulus deprivation amblyopia. This aspect together with the higher difficulty in the pediatric observation, make the characterization of these cases a challenge and sometimes the confirmation of the diagnosis is only performed intraoperatively.

Methods: Description of the case of a patient with the initial diagnosis of unilateral congenital cataract, which intraoperatively was revealed to be only a PPM.

Results: A six-week-old boy, with no relevant personal and family history, was referred to the pediatric ophthalmology consultation with the diagnosis of possible congenital cataract of the left eye due to leukocoria. At biomicroscopy this eye had a central white opacity with a moderate density, adhering to the pupillary margin between 4 and 8 hours through two brown branched portions, which limited the observation of the ocular fundus. The right eye was normal. Given the hypothesis of congenital cataract and the difficulty of a complete observation, and also to prevent amblyopia, it was decided to undergo intraoperative observation with eventual lens surgery. The extent and the adhesion degree of the membrane to the pupillary border and to the anterior capsule of the lens were initially analyzed using a visco-surgical device and a spatula. The membrane strands were cut with vitreous scissors and the membrane with apparent central lens opacity was removed with visco-surgical device. This opacity was found to be only fibrovascular material resulting from the extension of the pupillary membrane fragments. The procedure was carefully performed to avoid any traction in the anterior capsule and contact with the crystalline lens, which proved to be transparent, not requiring cataract surgery.

Conclusion: Depending on its characteristics, PPM can integrate the differential diagnosis of congenital cataract, with a better intraoperative characterization and an eventual modification of the surgical plan. In the case described, the early surgical approach of the PPM without cataract and the good anatomic result will contribute to a better visual prognosis.



P 27

Phacoemulsification followed by placement of a toric intraocular lens in a child with bilateral lamellar cataract

Jorge Meira, Augusto Magalhães, Jorge Breda, Fernando Falcão-Reis

¹ Department of Ophthalmology, Centro Hospitalar de São João, Porto, Portugal

² Faculty of Medicine, Porto University, Porto, Portugal

Speaker: Jorge Meira

Introduction: Lamellar cataracts are one of the most common form of congenital cataracts. They are usually seen bilaterally in early childhood but may be congenital in onset. Fine, dispersed, pulverulent opacities of the primary fibber lens are seen in the embryonic nucleus often with increased density at the ends of the Y suture at 12, 2, and 6 o'clock presenting a triangular appearance. However, the entire nucleus may be opaque as well. Due to their progressive nature, they can lead to severe impairment of visual acuity and amblyopia, thus having a surgical indication.

In the presence of simultaneous corneal astigmatism, the placement of intraocular toric lenses is a surgical challenge, but when performed successfully, it results in good functional result, with great satisfaction on the part of the patient and his family.

Material and Methods: A case of a 9-year follow up of a 4 year-aged boy with lamellar cataract with recent visual acuity deterioration and acute progressive myopia is reported. A brief review of articles published, using the Pubmed database, was performed.

Results: Although at the early stage cataracts did not cause significant decrease in visual acuity, during the follow-up period an important evolution of the nuclear component of the cataract was observed, with acute progressive myopia and visual acuity impairment. Given the high myopia and astigmatism of the child ($-8.00 -3.00 \times 30^\circ$ // $-6.50 -3.00 \times 30^\circ$) it was decided the placement of an intraocular toric lens (Acrysof I.Q. Toric). The surgery went without complications. One month after surgery, the child had visual acuity of 20/25 in both eyes, with minimal residual astigmatism.

Conclusion: Although it is a surgical challenge, the placement of intraocular toric lens in selected children provides a virtual postoperative emmetropia that contributes greatly to good functional result, better quality of life and satisfaction of patients.

P 28

Long Term Results in Cystinosis Treated with 0,55% Cysteamine Hydrochloride Solution

Pilar Tejada-Palacios, Ana Ortueta-Olartecoechea, Julia Vara-Martín, Mar Espino-Hernández, Cristina López-López, Ana Barceló-Mendiguchia

Hospital Universitario 12 de Octubre, Madrid, Spain

Speaker: Ana Ortueta-Olartecoechea

Introduction: Cystinosis is a hereditary systemic disease, characterized by accumulation of the amino acid cystine. Cystine crystals accumulate in the cornea, the conjunctiva, iris, ciliary body, choroid and retinal pigment epithelium. The crystals located in the retina respond to treatment with oral cysteamine; however, this treatment is not effective in the cornea, consequently it is necessary to administer topical treatment.

Methods: We present two case reports of two children with this condition that have been treated with 0,55% cysteamine hydrochloride solution for 4 and 5 years.

Results: The two children aged 7 and 9 years were diagnosed at 7 and 8 months of Fanconi syndrome. They presented high concentrations of intraleukocytic cystine and mutation in the CTNS gene. From the diagnosis they received oral treatment with cysteamine. Routine ophthalmological examination at the age of 2 and 4 years showed deposits of cystine crystals in the corneal epithelium and stroma. They started treatment with the topical cysteamine gel formula (CH 0.55%) 3-4 times a day. They were reviewed every 3-6 months and slit lamp examination and anterior segment OCT were performed.

Both cases presented decrease in the photophobia grade and corneal crystals after 4 and 5 years of treatment.

Visoperceptive screening test were carried and in both patients they were very altered. The neurocognitive report pointed out deficits related to spatial attention and visuospatial processes.

Conclusion: Cysteamine eye drops 0.55% viscous solution has been effective in our patients for the reduction of corneal crystals. The anterior segment OCT has been useful for monitoring the treatment. The better tolerance and decrease of number of applications of the new gel formulations leads a better therapeutic compliance and a better life quality. It is also important to assess these patients visuoperception, because immaturity in spatial and visual-motor perceptual functions prevents proper learning and noticing them can improve these children's school performance.



Poster Abstracts

P 29

Ectodermal dysplasia syndrome in childhood

Andrea Szigeti, Mária Csidey, Ágnes Ildikó Takács, Zsuzsanna Antus, Olga Lukáts, Mária Bausz, László Imre, Anna Szamosi, Zoltán Zsolt Nagy, Erika Maka

Department of Ophthalmology, Semmelweis University, Budapest, Hungary

Speaker: Andrea Szigeti

Purpose: Ectodermal dysplasia syndrome (EDS) is a group of hereditary diseases characterized by damage of ectodermal tissues. With the presentation of our cases we reviewed the ophthalmic aspects of the EDS in childhood.

Case-reports: We present 4 children with EDS: a 14-year-old boy with Rapp-Hodgkin syndrome, a 7-year-old girl with hypohydrotic EDS, a 12-year-old and 13-year-old brother with ectrodactyly-ectodermal dysplasia-clefting-syndrome.

Discussion: Different ocular disorders can occur in EDS, dry eye syndrome is the most common caused by abnormal tear film (partial or complete absence of Meibomian glands, impaired function or absence of lacrimal gland and/ or conjunctival goblet cells), which can associate with recurrent ocular inflammations, like keratitis may progress to corneal perforation in serious cases. Because of the extraocular manifestations of EDS, the complex rehabilitation of children with EDS must be carried out in cooperation with pediatricians and dentists.

P 30

Ocular manifestations in Loeys-Dietz syndrome: a case report

Nathalie Voide¹, Jacques Durig¹, Luisa Bonafé², Ana Belinda Campos Fernandes Xavier², Georges Klainguti¹

¹ Jules Gonin Eye Hospital, Lausanne, Switzerland


² Center for molecular diseases, Lausanne University Hospital, Lausanne, Switzerland

Introduction: Loeys-Dietz syndrome (LDS) is an autosomal dominant connective tissue disorder affecting cardiovascular, skeletal and ocular system. We report a case of a 13 year-old girl affected by LDS who presented atypical ocular manifestations compared with the usual descriptions.

Case presentation: The patient was referred for evaluation of recent asthenopia in the context of decompensated partially accommodative convergent microstrabismus (DPACM) with convergence excess (CE) and hypo-accommodation (HA). Other ocular signs included blue sclera, hypertelorism, proptosis with lagophthalmos, astigmatism and high hyperopia, ocular hypertension controlled by topical beta-blockers and thin corneal thicknesses (517µm). Systemic signs included transmission deafness, aortic root dilation, mitral insufficiency, cerebral arteries tortuosity, retrognathia, malar flattening, operated clubfeet, pectum excavatum, scoliosis and joint hyperlaxity. A de novo loss-of-function mutation, c.989G>A, p.Arg330His in the TGFB2 was found. Familial history was remarkable for convergent strabismus (CS) in the father and brother, both unaffected from LDS and not carriers of the mutation.

Discussion: LDS is usually associated with divergent strabismus and myopia unlike our patient. This unusual clinical presentation could be influenced by the familial history, independently from the TGFB2 mutation. However, the asthenopic symptoms described as ocular pain and increase of CS with HA could be related to the TGFB2 mutation. The pathogenetic mechanism of TGFB2 loss-of-function mutations in LDS have been shown to be linked to hyperactivity of TGFB1 signaling, that is one of the molecular mechanisms involved in aging of the eye anterior segment, together with loss of autophagy and oxidative stress. Furthermore, TGFB1 hyperactivity has been associated with ocular hypertension.

Conclusion: To our knowledge, this seems to be the first presentation of DPACM with CE and HA causing significant asthenopia in a patient with LDS. We formulate the hypothesis that hyperactivity of TGFB1 signaling may be involved in the ocular manifestations as it has been shown in the vascular wall, mimicking the molecular changes seen in premature aging of the ciliary body function, which favors the HA. Beside treatment with an angiotensin II type 1 receptor blocker which reduces TGF-beta signaling, we propose anti-oxidants to protect connective tissues and ocular structures from additional aging processes.



P 31

Assessment of retinal microcirculation damage using OCT angiography in a child with Hodgkin's lymphoma

Cecília Czako¹, Gábor László Sándor¹,
Hajnalka Horváth¹, Mónika Csóka²,
Zoltán Zsolt Nagy¹, Erika Maka¹

¹ Semmelweis University, Department of Ophthalmology

² Semmelweis University, 2nd Department of Pediatrics

Speaker: Cecília Czako

Purpose: To present a case of a child with recurrent Hodgkin lymphoma and binocular visual impairment.

Methods: Case report

Results: A 17-year-old boy with a 4-month-old history of binocular visual impairment presented at our hospital. Since the age of 8, he had been undergoing treatment due to recurrent Hodgkin lymphoma through chemotherapy, irradiation, autolog, and allogenic stem cell transplantation. He had previously had a medical history of several hospitalizations due to infectious complications. Six months before presentation he was hospitalized in an intensive care unit due to septicemia and three months later due to a stroke. At presentation his visual acuity was 0.4 in the right eye and 0.1 in the left. Slit lamp biomicroscopy, funduscopy, optical coherence tomography (OCT), and OCT angiography (OCTA) were performed. The right eye exhibited a macular scar, the left eye an atrophic macula at the posterior pole with dot hemorrhages along the inferior temporal vessel arcade and various peripheral scars on the fundus examination. OCT confirmed macular atrophy and OCTA showed retinal capillary vessel dropout in both eyes. Three months after his first presentation, visual acuity and fundus picture remained stable with OCTA revealing an increased retinal capillary circulation in both eyes.

Conclusion: In our case, OCT angiography proved to be an excellent non-invasive imaging technique in assessing decreased retinal capillary circulation which was resulted from circulatory disturbance.

Keywords: optical coherence tomography angiography, retinal capillary dropout

P 32

Sludge phenomenon in patients with type 1 of Retinopathy of Prematurity

Natalya Fomina¹, Elvira Saidasheva¹,
Elena Goravskaya²

¹ North-West State Medical University named by I.I.Mechnikov, St.Petersburg, Russia

² Hospital №17 of St. Nicolas, Sankt-Petersburg, Russia

Speaker: Natalya Fomina

Introduction: The erythrocyte aggregation has a key role in the rise of the intravascular microcirculatory disorders. Conditions, which cause of "sludge phenomenon", include infections, inflammatory, shock, arterial hypertension and malignant tumours. It also occurs in diabetes melitus and is one of the causative factors for microvascular occlusion in diabetic retinopathy. But we didn't find prescription of this phenomenon in premature babies with Retinopathy of Prematurity.

Methods: Case report

Results: Case 1: Boy A. was born at 26 week of gestation age with birth weight 790 g. He had Apgar scores of 4 and 6. He was intubated with FiO₂ - 0,4 and was given one dose of a surfactant preparation. He was extubated at 31 week of postconceptual age (PA) but he was required supplemental oxygen through the 34-th week of PA and baby had recurrent apnoea and frequent unprovoked desaturation episodes. The boy had 4 blood transfusions because of anaemia. Ophthalmologist examined him at 31 week of PA - the signs of immature retina and optic system were registered. At age of 34 week of PA he had the diagnosis of ROP: zone II, Stage II, pre-plus disease. At age of 34,5 week of PA we observed the appearance of sludge phenomenon in central vessels of his retina. Case 2: Girl P. the second from twin, was born at 28 week of gestation age with birth weight 1120 g. He had Apgar scores of 7 and 7. She was given one dose of a surfactant preparation. She wasn't intubated but she had apnoea 2 times a day in first 3 days of her life. She required supplemental oxygen through the 30th week of PA. ROP: zone II, Stage I, pre-plus disease was diagnosed at 32 week of PA. She had anaemia since that period. At age of 33 week of PA we observed the appearance of sludge phenomenon in vessels of the retina and chorioretinitis.

A few days after appearance of sludge symptom Type 1 ROP was registered and both babies were treated by diode laser. In both cases babies had apnoea, anaemia and infections which cause of "sludge phenomenon". The appearance of sludging erythrocytes in central vessels of the retina may be an important sign of development type 1 of ROP in a few days.

Conclusion: In recent years, there has been a search for software to evaluate changes in the fundus of the eyes in the ROP. We see the prospects for assessing not only the tortuosity of the vessels, the number of newly formed vessels, but also intravascular changes, such as the "sludge" phenomenon seen on RetCam and FA.



Poster Abstracts

P 33

The role of morphometric parameters of optic nerve head and retina in the diagnosis of congenital glaucoma in premature infants

Liudmila Kogoleva, Liudmila Katargina, Ekaterina Mazanova

Moscow Helmholtz Institute of eye diseases, Moscow, Russia

Purpose: To study the role of morphometric features of the optic nerve head and retina in the diagnosis of congenital glaucoma in premature infants.

Methods: Children with congenital glaucoma (21 children) with favorable outcomes of 1-3 degrees of retinopathy of prematurity (ROP) aged from 6 months to 12 years were examined (group I). The control group consisted of 32 full-term children with congenital glaucoma (group II). In addition to the standard methods of examination, Heidelberg retinal tomography (HRT) and optical coherence tomography (Spectralis-OCT) of optic nerve head (ONH) and retina were used.

Results: According to clinical manifestations of glaucoma, there were no significant differences between the groups. In congenital glaucoma in children with 1-2 degree of ROP, as in full-term infants with congenital glaucoma, revealed the same pronounced morphometric changes in structures, all zones of the disk and zones peripapillary retina, which is characteristic for the development of glaucomatous optic neuropathy and exacerbates progression of glaucomatous process. Interpretation of head changes were hampered in patients with 3 stage of ROP by traction to deformation of the ONH and displacement of the vascular bundles. We have not revealed a clear link between the changes in the optic nerve disk and the indicators of IOP.

Conclusion: Measurement of morphometric parameters and number of identified in this paper pathognomonic symptoms of optic nerve and peripapillary retina damage in congenital glaucoma in premature infants obtained in the work are necessary for studying the pathogenesis of glaucomatous process in ROP, clarifying the diagnosis, determining the prognosis of the disease, assessing the stabilization of the glaucomatous process and developing treatment tactics.

P 34

Reproducibility of OCT-Angiography in Children

Stefan Langenegger¹, Ender Konukoglu², Held Ulrike³, Klaus Steigmiller³, Fabienne Fierz¹, Gerth-Kahlert Christina¹

¹ Department of Ophthalmology, University Hospital Zurich, Switzerland

² Computer Vision Laboratory, ETH Zurich, Zurich, Switzerland

³ Institute for Epidemiology, Biostatistics, and Prevention

Speaker: Stefan Langenegger

Introduction: The recent development of OCT Angiography (OCTA) enables the display of retinal perfusion without the use of intravenous dye offering a non-invasive alternative to fluorescein angiography (FA). Moreover, OCTA can display superficial retinal and deeper layer choroidal vascularization as well. Being a non-invasive and relatively fast technique, OCTA seems to be highly suitable to examine children. With our study, we evaluated the image reproducibility and hence the quality of OCTA scans of children (6-18 years old) obtained in a real-life clinical setting.

Methods: We obtained repeated OCTA scans with various resolutions in different sizes and with two different devices (Zeiss PLEX Elite 9000 Swept-Source OCTA, Heidelberg Spectralis SD OCTA) in the same subjects (n=17). OCTA Scans were subdivided into sectors of an ETDRS-Grid with one additional narrowing circle to improve the central discrimination. Mean image intensity was computed for each sector in every OCTA obtained. Mean image intensities of two subsequently acquired examinations within the same subject and with the same device and settings were used to calculate reproducibility of the examination. Intra-subject reproducibility was compared for each sector within different examination protocols to identify the examination technique with the best reproducibility. Inter-subject discrimination was calculated to reassure the discrimination between different subjects. The study was approved by the local ethics committee.

Results: Mean Intra-subject reproducibility over all sectors as measured by coefficient of variation (COV) was between 3.4% and 9.3%. Reproducibility for OCTA scans obtained with Zeiss PLEX Elite 9000 Swept-Source OCTA was slightly better than for scans obtained with Heidelberg Spectralis SD OCTA. In OCTA scans obtained with Spectralis SD OCTA mean COV was not lower in images obtained with higher scan quality (HR, COV 9.3%) as compared to scans with high-speed scan quality (HS, COV 6.4%).

Conclusion: Our data suggest that reproducibility of OCTA is good in children. Higher resolution scans did not improve measurement reproducibility as quantified by this method. Higher OCTA scan quality might not improve reproducibility. Better reproducibility was correlated with shorter examination time even if the shorter examination time came at the price of lower scanning resolution.



P 35

Breastfeeding: role in the progression of retinopathy of prematurity to the threshold stages

Elvira Saidasheva, Marina Petrachkova

North-Western State Medical University named after I.I.Mechnikov, Saint Petersburg, Russia

Speaker: Elvira Saidasheva

Introduction: The study is devoted to the evaluation of the breastfeeding effect of neonates on the progression of retinopathy of prematurity (ROP) to the threshold stages.

Methods: 50 histories of the case of premature neonates with different stages of ROP were studied retrospectively. Neonates were divided into 2 groups: group 1-23 (45 eyes) included the neonates with an established diagnosis of the threshold stage of ROP, which required laser surgical treatment, group 2 consisted of 27 (53 eyes) neonates with active ROP, resulting in spontaneous regression. The type of feeding was determined by the use in the neonatal period of the enteral product: natural - native breast milk, mixed - breast milk with a specialized mixture for preterm infants and artificial - a specialized mixture for premature newborns.

Results: The mean neonates birth weight (BW) in the group 1 was 1095.80 ± 317.89 g, in group 2 - $1,169.07 \pm 312.14$ g ($p = 0.204$). The mean gestational age (GA) in the group 1 was 27.73 ± 2.35 weeks, in the group 2 - 28.41 ± 2.21 weeks ($p = 0.137$). Breast milk received 41% (9) of neonates in the group 1 and 64% (17) - in the group 2 ($p < 0.05$). Neonates who were exclusively breastfed in the group 1 were not present, while in the group 2 of such neonates there were 14% (4). In group 2, the number of neonates receiving only the mixture was 23% less than in the case of neonates in group 1: 36% (10) and 59% (14) respectively ($p < 0.05$). The increment of WB for 1 month of life in the children of the study groups was 349 ± 26.1 g (11.6 g / day) and 465 ± 170.4 g (15.5 g / day) respectively ($p < 0.05$).

Conclusions: The presence of breast milk in the nutrition of premature newborns can be considered as a protective factor that reduces the likelihood of ROP progression to the threshold stages and, therefore, avoid laser surgical treatment.

P 36

Insidious Late Malignant Transformation of a Retinoma

Jessica Sergenti, Christina Stathopoulos, Marie-Claire Gaillard, Alexandre Moulin, Ann Schalenbourg, Francis Munier

Jules-Gonin Eye Hospital, Fondation Asile des Aveugles, Lausanne, Switzerland

Speaker: Sergenti Jessica

Purpose: To report an insidious case of late malignant transformation of a retinoma in a 52-year-old patient.

Methods: Case report

Results: A 52-year-old female with no history of ophthalmic disease consulted elsewhere for floaters and partial scotomas in her left eye occurring over the previous five months. Left eye examination showed normal anterior chamber with no rubeosis and multiple white retinal masses located on the optic nerve head as well as in mid- and extreme periphery, sparing the macula but with extensive vitreous involvement. Right eye was unremarkable. Cerebral and orbital MRI showed multiple retinal tumors with no invasion of the orbit or central nervous system involvement. PET, total-body CT, colonoscopy, esophagogastroduodenoscopy and complete blood count were reported negative. A diagnosis of intraocular lymphoma was presumed and a diagnostic pars-plana vitrectomy (PPV) was performed. Cytological analysis did not, however, confirm the diagnosis. Two months after the PPV the patient developed a complete retinal detachment. Proton beam radiotherapy was discussed as a treatment option but ultimately the patient was referred to Jules-Gonin Eye Hospital for a second opinion.

A retinoma as well as a primary retinoblastoma infiltrating the ciliary body and vitreous seeds were identified. Diagnosis of sporadic retinoblastoma resulting from malignant transformation of a previously undetected retinoma was presumed. A new orbital MRI was performed. Enucleation was preferred due to ciliary body involvement, tumor growth on the optic nerve and chronic retinal detachment. Histopathologic findings will be further discussed.

Conclusion: Retinoma is a benign tumor caused by bi-allelic loss of RB1 with the potential for malignant transformation when additional oncogenic mutations occur. The case of this 52-year-old female emphasizes that there is no time limit in the latency between spontaneous regression during infancy and malignant transformation and that annual fundus controls in retinoma patients should never stop.



Poster Abstracts

P 37

Cerebellar cognitive syndrome in a preterm child. Case report

Pilar Tejada-Palacios, Jose Torres-Peña, Ana Ortueta-Olartecoechea, Maria Torres-Valdivieso, Ana Martinez-de-Aragon, Berta Zamora-Crespo
Hospital Universitario 12 de Octubre, Madrid, Spain

Speaker: Jose Torres-Peña

Introduction: The involvement of the cerebellum in motor processes through the coordination of movement is known, however, it is around 1940s that articles involving the cerebellum in non-motor functions, such as cognitive processing or emotions. The Cerebellar cognitive affective syndrome is characterized by disturbances of executive function, impaired spatial cognition, linguistic difficulties, and personality change.

Methods: The case of a five year old boy with medical background of extreme prematurity and triplet is presented, with behavior problems, learning difficulties and social interaction problems. In the physical examination he presented best corrected visual acuity 0.8 in right eye and 0.9 in left eye poor visual contact, immature behavior, reduced expressive language and global motor disability with gait dyspraxia, with no defined cerebellar motor signs. In our functional exploration we found a visual-perceptual disorder and In the neuropsychological evaluation he has a full scale overall intellectual quotient of 86, with signs of cerebellar cognitive syndrome. A cerebellar atrophy was observed in the magnetic resonance imaging.

Results: The diagnosis was useful making recommendations to the education center for an appropriated rehabilitation and interaction with the others children.

Conclusion: The cerebellum participates in controlling cognitive and affective functions. Cerebellar pathology must be considered in the differential diagnosis of children with cognitive or learning disorder with associated behavioral and emotional components.

P 38

Cerebral MRI Freesurfer Volumetry in Preterm Children with Visual Dysfunction

Pilar Tejada-Palacios, Isabel Martínez-Tejada, Ana Martínez de Aragón, Berta Zamora-Crespo, Cristina López-López, Ana Ortueta-Olartecoechea
Hospital Universitario 12 de Octubre, Madrid, Spain

Speaker: Ana Ortueta-Olartecoechea

Introduction: Premature children have a higher visoperceptive disorder risk within neurocognitive damage. A relationship between white matter (WM), gray matter (GM) and corpus callosum (CC) volumes in the brain and neurocognitive damage may exist. The objective of this pilot study is to quantitate the 3D brain volumetric (BV) data of 6 former prematures with visoperceptive disorder diagnosed at the age of 5.

Methods: BV analysis were carried out according to their magnetic resonance imaging (MRI) scans. Using FreeSurfer v5.1 software the total BV volume measurement as well as the GM, WM and CC volumes were calculated.

Results: In all 6 patients included in this pilot study the total brain volume, and the GM, WM and CC volumes estimated were lower than expected.

The child with the most serious visoperceptive disorder showed the lowest volumes in all structures. It must be noted that the child who only showed focal WM alteration in the structural MR also showed lower volumes in the volumetric analysis.

Conclusion: The results obtained in our work demonstrate the validity of this tool and the BV measurements in premature children, with outstanding applications in the foreseeable future, as the one proposed herein. Thus, the brain volumetric analysis performed on MRI scans may potentially be an excellent biomarker of the visoperceptive disorders in prematurity.



P 39

Macular thickness in extreme premature born child

Jose Torres-Peña, Ana Ortueta-Olartecoechea, Alicia Muñoz-Gallego, Maria Torres-Valdivieso, Javier de-Lacruz, Pilar Tejada-Palacios
Hospital Universitario 12 de Octubre, Madrid, Spain

Speaker: Jose Torres-peña

Introduction: Previous studies have revealed various subnormal visual functions in prematurely born children. The present study aimed to describe the retinal macular thickness in extremely prematurely born children (32 weeks or less).

Methods: The eyes of 138 extreme premature born children aged 5 - 11 years were examined with TOPCON 3D-2000 optical coherence tomography (OCT). The retinal macular thickness in the nine EDTRS macular areas (A1-A9), the foveal minimum and the total macular volume were determined.

Results: The central macular thickness was significantly thicker in the prematurely born children with less than 28 weeks than in those born between 28 and 32 weeks ($P < 0.05$). There was no correlation between macular thickness and visual acuity or refraction. Children with previous retinopathy of prematurity (ROP) had thicker central maculae with $p > 0.05$.

Conclusion: In extreme prematurely born children less than 28 weeks had thicker central maculae than those born between 28 and 32 weeks. Regardless of ROP, the degree of prematurity was the most important risk factor for abnormal foveal development than persist until childhood.

P 40

Two cases of congenital blindness caused by exudative vitreoretinopathy

Flóra Tóth¹, Viktória Szabó², Kálmán Tory³, Éva Hosszú⁴, Béla Csákány², Erika Maka²

¹ Ferenc Flor Hospital, Kistarcsa, Hungary

² Department of Ophthalmology, Semmelweis University, Budapest, Hungary

³ 1st Department of Pediatrics, Semmelweis University, Budapest, Hungary

⁴ 2nd Department of Pediatrics, Semmelweis University, Budapest, Hungary

Speaker: Flóra Tóth

Case report: Two non-preterm, 2-month-old boys with bilateral total retinal detachment were referred to our department in the last some years. Family history was negative in both cases. To confirm the clinical impression of familial exudative vitreoretinopathy (FEVR)/Norrie syndrome, genetic tests were performed.

In the first case molecular testing showed a missense mutation in the Norrin gene c.38T>C (predicted protein change p.Leu13Pro). Mutations in the NDP gene can cause Norrie disease and X-linked FEVR. Sequential hearing testing and speech therapy are essential. Educational and intellectual expectations for this child should be monitored also. The baby's hearing screen was normal. We confirmed that the mother is a carrier.

In the second case, the family has had the coding exons of NDP gene sequenced with no results. Sequence analysis using the Blueprint Genetics (BpG) Vitreoretinopathy Panel identified heterozygous 2-bp deletion c.4298_4299del, p.(Val1433Alafs*116) in LRP5 and a heterozygous missense variant c.3842A>T, p.(Asp1281Val) in LRP5. Mutation in the LRP5 gene can be inherited in an autosomal dominant or autosomal recessive manner. Mutations in LRP5 have been associated with FEVR, hyperostosis, osteopetrosis and van Buchem disease, type 2 as well as autosomal recessive osteoporosis-pseudoglioma (OPPG) syndrome. In this case the osteodensitometry showed significant lower Z score in the lumbar vertebra.

Conclusion: In both cases pathogenic gene mutations were found. Patients of the severe form of the FEVR spectrum are more likely to have the extra-ocular features, that the clinician should take notice of. In Norrie disease mental retardation and deafness are present, in OPPG fractures or reduced bone density in childhood are associated.



Poster Abstracts

P 41

Foveal hypoplasia in aniridia

Mária Csídey, Cecília Czákó, Krisztina Knézy, Zoltán Zsolt Nagy, Erika Maka

Department of Ophthalmology, Semmelweis University, Budapest, Hungary

Speaker: Mária Csídey

Introduction: Aniridia is a bilateral, panocular disorder caused by PAX6 gene mutation. It is characterized by variable degree of hypoplasia or absence of iris. Aniridia is not just an isolated defect in iris development it is associated with foveal and optic nerve hypoplasia.

Methods: 23 eyes of 13 people from 7 non consanguineous families were investigated. Female-male ratio: 8:5, average age: 18,9 years. Best corrected visual acuity was measured with ETDRS optotypes and the morphologic features of fovea was analysed by Angio Vue Optical Coherence Tomography (OCT) (Optovue Inc. Fremont USA). Foveal hypoplasia grading was made by Thomas Structural Grading of Foveal Hypoplasia (Grade1: absence of plexiform layers' extrusion; Grade 2: absence of foveal pit; Grade 3: absence of outer segment lengthening; Grade 4: absence of outer nuclear layer widening).

Results: The mean best-corrected visual acuity was 0.5. Foveal hypoplasia was observed in all cases. Foveal hypoplasia distribution was grade 1 in 1 eye, grade 2 in 10 eyes, grade 3 in 4 eyes, grade 4 in 7 eyes.

Conclusion: The OCT can be used to determine the severity of foveal hypoplasia. We couldn't find any differences between two eyes in the severity of foveal hypoplasia. OCT method can be used in patients with nystagmus. The OCT recordings couldn't be evaluated in the presence of corneal or lens opacities.

P 42

Pigmented paravenous retinochoroidal atrophy in a boy with atypical Inflammatory Bowel phenotype of NCF1 mutation (Chronic Granulomatous Disease)

Sabine Defoort-Dhellemmes, Vasily Smirnov, Bernard Puech, Frédérique Gottrand, Brigitte Nelken

Centre Hospitalier Universitaire de Lille, Lille, France

Speaker: Sabine Defoort-Dhellemmes

Introduction: Pigmented paravenous retinochoroidal atrophy (PPRCA) is a relatively stationary degeneration of external retina with a specific pattern of lesion distribution. Some cases were reported as post-infectious (tuberculosis, syphilis, measles and rubella) or post-vaccinal.

Patient: We report here a case of a 3 year-old boy with a PPRCA discovered at the routine ophthalmic examination after a febrile seizure. Multimodal fundus imaging with functional correlations will be presented. At the repeated ophthalmic assessment, we noted a chronic diarrhoea with a weight stagnation. Gastroenterological examination revealed a severe Crohn-like Inflammatory Bowel Disease. Standard therapy was inefficient and led to multiple complications. Further investigations revealed altered neutrophilic function. Homozygous NCF1 mutation was found in this patient thus confirming the diagnosis of Chronic Granulomatous Disease.

Discussion: The inflammatory origin of PPRCA is usually discussed but few cases were undoubtedly linked with inflammatory/infectious events. Predominantly perivascular outer retinal destruction supporting the probable immune mechanism of lesions. Interestingly, our little patient had initially a cystoid macular edema which resolved with infliximab treatment, another argument supporting the inflammatory hypothesis.



P 43

An Interesting Case of Rod-Cone Dystrophy in a Child

Lucia Derriman, Vicki Sandford, Abbas Toufeeq
Royal Berkshire NHS Foundation Trust, Reading,
United Kingdom

Speaker: Lucia Derriman

Introduction: A 15 year old girl presented to the Eye Casualty, having been referred via her optician with a 3 month history of headaches, reduced vision and poorly defined, raised optic disc margins. There was no previous ophthalmic history, no past medical history and she took no regular medicines. She had no family history of ocular disorders of a hereditary nature.

Methods: On examination, VA on Snellen was 6/9.5 Right, 6.7.5 Left. Detailed ophthalmic examination was not conducted on initial review as it was clear on fundoscopy that she had bilateral disc swelling; the child was therefore admitted under the Paediatric team for urgent investigations and medical work up.

Results: Paediatricians found the child to be systemically well and there was no focal neurology; all blood tests including infection screen and vasculitis screen were normal. MRI head and MRV were normal. She then had a lumbar puncture which revealed normal CSF opening pressure of 18cms and no clear cause was found for her disc swelling. The child was examined again in detail in the Eye Outpatient Clinic. VA was stable in both eyes on Snellen, anterior segment exam was normal in both eyes but there was still bilateral disc swelling, which on ultrasound B-scan did not appear consistent with a diagnosis of drusen. In addition, OCT confirmed tiny peripapillary intraretinal cysts of fluid extending to but not involving the fovea in both eyes. Additionally, subtle pigmentary changes, some of bone spiculae type, were noted in the extreme periphery of both retinas. She also had bilateral marked constriction of her fields on formal testing.

The child was sent for Electrodiagnostic tests, which confirmed broadly normal macular and visual pathway responses, despite the abnormal disc appearance. General retinal function however was significantly reduced in amplitude and results were in keeping with a rod-cone dysfunction such as retinitis pigmentosa (RP).

The child was sent for further genetic testing and is awaiting the results.

Conclusion: Pseudopapilloedema, with and without disk drusen, is a common association with RP. However, papilloedema has been reported rarely (even in adults) in association with RP. To our knowledge, this is the youngest case of bilateral disc oedema associated with rod cone dystrophy reported in the literature and is unique in that there were no other systemic causes associated with her ocular findings.

P 44

Acute posterior multifocal placoid pigmentary epitheliopathy – case report

Valéria Gaál, Krisztina Lantos, Ilona Szabó, Zsolt Biro

Department of Ophthalmology University of Pécs,
Pécs, Hungary

Speaker: Valéria Gaál

The APMPE is one of the rare white dot syndromes. The authors introduce the case of a 15-year-old girl and summerise the most important facts regarding this disease.





Poster Abstracts

P 45

Incomplete Vogt-Koyanagi-Harada Disease in a 4.5-year-old Boy

Špela Markelj¹, Mirjana Perkovič Benedik²,
Branka Stirn Kranjc¹, Manca Tekavčič Pompe¹

¹ University Eye Hospital Ljubljana, Slovenia

² University Children's Hospital Ljubljana, Slovenia

Speaker: Špela Markelj

Introduction: Vogt-Koyanagi-Harada disease (VKHD) is a rare granulomatous inflammatory disease that affects pigmented structures, such as eye, inner ear, meninges, skin and hair. It is rarely seen in childhood. Based on fulfillment of diagnostic criteria we can differentiate complete, incomplete and probable VKHD. We are presenting a 4.5-year-old Caucasian boy with incomplete VKHD.

Methods: Case report

Results: A 4.5-year-old boy with atopic features and positive thick bite history experienced signs of upper respiratory tract infection with high fever. 10 days later he got headache and painful red eyes that did not respond to topical antibiotic drops. His visual acuity declined. At examination in our hospital his BCVA RE was 0,16; LE 0,3 Snellen. He had bilateral anterior chamber exudation 2+, vitreous cells, subfoveal serous retinal detachment and hyperemic optic nerve discs. His neurological status was normal.

EDI-OCT showed bilateral subfoveal serous retinal detachment and thickened choroid. Ultrasound revealed diffuse subretinal thickening of low - medium reflectivity, fluorescein angiography showed pinpoint hypofluorescence leakage on the posterior pole and in the mid periphery as well as optic nerve disc leakage. MRI excluded intracranial pathology. Microbiology workup with lumbar puncture excluded infective causes. Extensive rheumatologic evaluation was normal. Lumbar puncture showed reactive lymphocytosis without malignant cells. Antibodies against neuronal surface antigens were negative. On extensive physical examination, no specific skin or hair features were found. Based on his clinical presentation incomplete VKHD was diagnosed.

He was treated with metilprednisolone 1mg/kg (3 months tapering) and due to thick bite history intravenous antibiotics for 2 weeks. Visual acuity and clinical features resolved in less than a month. After discontinuation of corticosteroid treatment, he had relapse with anterior chamber reaction, that was successfully managed with topical corticosteroids. Three years after the episode his BCVE BE is 1,0 Snellen. On fundus, late sequelae such as depigmentation with reddish glow, RPE clumping in the macula and multiple well-defined hypopigmented white lesions in mid-periphery are seen.

Conclusion: VKH disease is rare in childhood but with timely recognition and prompt treatment favourable outcomes can be achieved.

P 46

Achromatopsia: diagnosis and treatment options. Case report and review of the literature

Lucía Ramos-González¹, Isabel Pascual-Camps²,
Clara Martínez-Rubio¹, Carla Villena-Alvarado¹,
Juan Aurelio Aviñó-Martínez¹,
Honorio Barranco-González¹

¹ Hospital Universitario y Politécnico La Fe, Valencia, Spain

² Hospital Provincial de Castellón, Castellón, Spain

Speaker: Lucía Ramos González

Introduction: Achromatopsia is an inherited retinal disease affecting the cone-photoreceptor function. It is usually an autosomal-recessive disease. It is characterized by pendular nystagmus, poor visual acuity, photophobia and lack of color vision. Mutations in CNGA3, CNGB3, GNAT2, PDE6C, PDE6H and ATF6 genes have been identified as cause of achromatopsia. Gene therapy is being studied for the treatment of these patients.

Methods: Case report of two siblings affected of achromatopsia. Clinical examination, electrophysiology tests, optical coherence tomography and genetic testing were performed.

Results: Both siblings presented with lack of fixation, nystagmus, photophobia and low visual acuity (20/100) in both eyes. Full field Electroretinogram showed responses with decreased amplitude for cones and rods. Macular optical coherence tomography showed ellipsoid layer disruption and macular hypoplasia. Genetic testing resulted in mutations p.R277H and p.R283W in the exon 7 of the CNGA3 gene on both siblings. The study of the proband's father resulted in heterozygous carrier of the p.R277H mutation; and the proband's mother resulted in heterozygous carrier of the p.R283W mutation.

Conclusion: Achromatopsia is a complex inherited disease, that can be diagnosed clinically, but its genetic approach is crucial for the future diagnosis and treatment of these patients. New diagnostic and therapeutic strategies are being studied for the management of these patients.



P 47

Long chain 3-hydroxyacyl-CoA dehydrogenase (LCHAD) deficiency - a 3-year follow up

Ricardo dos Santos Soares, Rosário Varandas, Maria Helena Santos

Centro Hospitalar Vila Nova de Gaia e Espinho, Braga, Portugal

Speaker: Ricardo dos Santos Soares

Introduction: Long chain 3-hydroxyacyl-CoA dehydrogenase (LCHAD) deficiency is a rare, autosomal recessive disorder of mitochondrial beta oxidation which leads to an anomaly in fatty acid metabolism, particularly during fasting. The signs and symptoms of this disease typically appear during infancy or early childhood and rhabdomyolysis, cardiomyopathy, polyneuropathy, hypoketotic hypoglycemia may develop. Most patients present ocular findings which include exotropia, pigmentary retinopathy, progressive myopia, cataract, visual defects and color vision abnormalities.

Methods: A case of a 3-year follow up of a 4 year-aged boy with LCHAD deficiency is reported. A multimodal study was performed - clinical examination, fundus examination, optical coherence tomography (OCT) and multifocal electroretinography findings during follow up are presented. A brief review of articles published, using the Pubmed database, was performed.

Results: Ocular abnormalities developed in a patient with LCHAD deficiency even though he received adequate nutritional treatment. At the age of 2 years, after systemic deteriorations, pigmentary retinopathy changes with "salt and pepper" scattering appear in both eyes. His retinography, OCT and multifocal electroretinography abnormalities are presented.

Conclusion: In spite of being rare, LCHAD deficiency presents with a pigmentary retinopathy that may rapidly progress despite nutritional treatment. A close follow-up of these patients is recommended.

P 48

Severe retinitis pigmentosa with posterior pole staphyloma in a family harbouring c.886 A>G RHO mutation

Vasily Smirnov, Bernard Puech, Claire-Marie Dhaenens, Sabine Defoort

Centre Hospitalier Universitaire de Lille, Lille, France

Speaker: Vasily Smirnov

Introduction: Posterior pole staphylomata were infrequently reported in association with inherited retinal degenerations. We report here a multimodal retinal imaging of a family suffering from a peculiar form of dominant retinitis pigmentosa (RP) with posterior pole staphyloma (PPS).

Patients: All the affected members complained of hemeralopia from their early childhood. 2 older brothers were first seen at the age of 5 et 10 years old, respectively. The eldest one had already a large PPS and the younger one developed it by the age of 10 years old. The youngest brother was examined at the age of 12 months old. His ERG was extinguished. He did not have PPS at this stage and was hyperopic, but the signs of posterior pole bowing became evident at 7 yo. There was no relation between the presence of PPS and refraction, patients with PPS were either hyperopic or myopic, but all have a high with-the-rule astigmatism. A myopic shift was observed for all the patients at follow-up visits.

Discussion: We could clinically observe a PPS development in initially non-myopic patients of a family with unusually severe dominant RP. In our patients the myopic shift was secondary to PPS formation. The PPS concerned only the area with relatively preserved outer retinal structures (ONL and EZ). Does the outer retina guide choroid and scleral remodelling?



Poster Abstracts

P 49

Acute macular neuroretinopathy in a young patient with an interferonopathy

Romain Touzé, Sarah Michel,
Dominique Brémont-Gignac, Matthieu Robert
Hôpital Necker-Enfants malades, Paris, France

Speaker: Romain Touzé

Introduction: Acute macular neuroretinopathy (AMNR) is a rare affection occurring in the macula area, described for the first time in 1975 by Bos and Deutman. The causes and pathophysiology are still not completely understood. A vascular mechanism is discussed. To the best of our knowledge, no case of AMNR associated with an interferonopathy has been reported so far. We describe a case of AMNR in a child with an interferonopathy.

Case report: A 14 year-old girl was referred to the ophthalmology department for an acute visual loss in the left eye since one month. She reported a flu-like episode one month previously. Her symptoms had appeared chronologically as follows: photopsia, then xanthopsia and finally visual impairment. Furthermore, she had a monogenic systemic lupus erythematosus with an antiphospholipid syndrome (APLS) treated by anticoagulant (Warfarine), in the context of an interferonopathy. Clinical examination was normal in the right eye; in the left eye visual acuity was 20/100. Left fundus examination showed a dark area in the inter papillo-macular region with stellar little perifoveal white dots. Goldmann visual fields showed a para-central scotoma. The lesion was hyporeflective on infrared imaging and mildly hypo-autofluorescent on fundus autofluorescence. Spectral domain showed a hyper-reflective band at the junction of the outer nuclear layer and outer plexiform layer and an ellipsoid zone disruption. Multimodal imaging therefore exhibited the features of AMNR type 2.

Discussion and conclusion: The most favoured explanation for this disease is a microvascular phenomenon occurring in the deep capillary plexus. In this severe paediatric case, although the child was treated by anticoagulant, the disease was insufficiently controlled when she developed AMNR, which is in accordance with the presumed pathophysiology.

P 50

Atypical retro internal limiting membrane hemorrhage in homozygous sickle-cell disease: a case report

Nathalie Voide, Irmela Mantel, Aude Ambresin
Jules Gonin University Eye Hospital, Lausanne, Switzerland

Speaker: Nathalie Voide

Introduction: Sickle-cell disease (SCD) is an inherited blood disorder known to cause several ocular complications associated with chorioretinal vaso-occlusive phenomena and spontaneous retinal hemorrhages. We report a case of a nineteen years-old woman affected by homozygous SCD that presented with an acute unilateral paracentral scotoma with floaters due to a solitary retinal lesion observed on her fundus.

Clinical Case: The patient affected by homozygous SCD, alpha thalassemia and systemic lupus erythematosus treated by hydroxychloroquine (200mg/d) and immunosuppressive therapy (Myfortic®, acidum mycophenolicum 360mg/d) was regularly followed in the last nine years in the Retina unit for a stationary sickle retinopathy classified as Goldberg stage II. She presented to the emergency department complaining with an acute right eye paracentral scotoma associated with floaters and preserved 20/20 best corrected visual acuity. Funduscopy showed a fuzzy yellow-white round-shaped intra retinal lesion located on the supero temporal vascular arcade without anterior chamber/vitreous inflammation or vasculitis. Structural OCT showed an hyperreflective material located under the ILM with intact neuroretina. Dye angiography showed a masking effect at the lesion site with stationary peripheral arteriovenous anastomoses and without any sign of retinal vasculitis. Because the patient was treated with immunosuppressive therapy and the lesion displayed atypical feature mainly the color for a recent hemorrhage, toxoplasmosis infection was ruled out by negative serology. Observation was carried out and spontaneous resorption occurred without treatment.

Discussion and Conclusion: Spontaneous hemorrhages are well described in sickle cell retinopathy, but usually take the appearance of salmon patches. In our case, the retinal hemorrhage showed a yellow-white appearance in the acute phase. We postulate that this color presentation of recent spontaneous hemorrhage could be due to heme sickling with rapid hemolysis after bleeding or concomitant use of immunosuppressive therapy. Careful review of multimodal imaging should be performed in case of acute retinal white lesion in a patient with SCD.



P 51

Optic neuropathy associated with intracranial arteriovenous malformations

Reem Farwana, Sahar Parvizi, Richard Bowman, Sanjay Bhate, I. Christopher Lloyd
Great Ormond Street Hospital, London, United Kingdom

Speaker: Reem Farwana

Introduction: Arterio-venous malformations (AVMs) are defects in the vascular system that can disrupt the cycle of normal tissue perfusion leading to hypoxia and, in the case of nerves, neuropathy. Available treatments include endovascular embolization, neurosurgery and stereotactic radiosurgery, with varying degrees of treatment-associated morbidity and mortality. We present two cases of intracranial AVM resulting in visual loss, one of which developed anterior ischaemic optic neuropathy (AION), and the other posterior ischaemic optic neuropathy (PION).

Methods: We retrieved patient data from electronic records at Great Ormond Street Hospital, London.

Results: Patient 1 presented asymptotically. MRI scans revealed a diffuse right sided AVM in the thalamus extending anteriorly over the orbital apex and ophthalmic artery. Fundal examination showed significantly tortuous vessels in the involved right eye. Electrodiagnostic testing suggested optic nerve dysfunction with visual acuity in the right eye (VA, logMAR) deteriorating from 0.14 (2016) to 1.4 (2018).

Patient 2 had an AVM closely associated with the left optic nerve resulting in optic atrophy, clinically visible on fundal examination with no other features. The likely mechanism for this was thought to be due to the vascular steal phenomenon and subsequent posterior ischaemic optic neuropathy. VA dropped from 0.24 in the left eye (2016) to 0.58 (2018). No treatments were deemed suitable for either patient.

Conclusion: As of yet, there are no satisfactory treatments with low morbidity and mortality available for AVMs. Our two cases of intracranial AVM illustrate their potential devastating effects on vision when closely related to the optic pathway.

P 52

Juvenile Idiopathic Arthritis Associated Uveitis – clinical features and complications

Hipólito Fernandes Diogo¹, Elisa Luis Maria¹, Cardigos Joana¹, Ramos Margarida², Conde Marta², Brito Cristina¹

¹ Department of Ophthalmology - Lisbon Central Hospital Center, Lisbon, Portugal

² Department of Pediatric Rheumatology - Lisbon Central Hospital Center, Lisbon, Portugal

Speaker: Diogo Hipólito Fernandes

Introduction: Juvenile idiopathic arthritis (JIA) is the most frequent rheumatic disease in paediatric population. Uveitis is the commonest extra-articular manifestation, typically with an insidious and asymptomatic presentation, the reason why ophthalmologic screening is fundamental.

The aim of this study was to describe clinical findings and analyse treatment evolution of a paediatric population with JIA-associated uveitis, followed in a tertiary hospital.

Methods: Retrospective cohort study of a population with JIA-associated uveitis. Patients were characterized according to their gender, age at diagnosis, JIA subtype, interval in years from rheumatic diagnosis to uveitis diagnosis, clinical features of uveitis, serologic laboratory findings, best corrected visual acuity (BCVA), treatment, complications and surgical procedures.

Results: A total of 24 patients were included, 13 (54,1%) females, with median age at uveitis diagnosis of 6 years (3,0-9,25) and median interval between arthritis and uveitis of 1 month (0-42). In 57,1% of patients, uveitis diagnosis occurred before or at the same time of JIA diagnosis and 80,9% until 4 years of disease. Oligoarticular arthritis was the most frequent subtype (58,3%). Anti-nuclear antibodies were positive in 70,8% of patients. Ophthalmologic complications were found in 12 patients (50%), with posterior synechiae being the most common (50%; 12/14), followed by cataracts (25%; 6/24). Five patients (20,8%) were submitted to surgery. At last follow-up, 6,25% of the eyes presented with a BCVA of less than 0,3 logMAR. A shorter time interval between rheumatic and ophthalmologic diagnosis was significantly related with development of complications (median=0; IQR 13 vs Median=36; IQR 64; p=0,034). Currently, 29,2% are on methotrexate as monotherapy and 20,8% on methotrexate plus adalimumab.

Conclusion: Most of JIA-associated uveitis occurred within first 4 four years of rheumatic disease. Approximately 50% of patients developed ophthalmologic complications, whose risk was higher when uveitis diagnosis was prior or concomitant of JIA diagnosis. These data corroborate the relevance of ophthalmologic screening in these population.



Poster Abstracts

P 53

Agressive Recurrent Orbital Plexiform Neurofibroma in a Child

Monica Gimeno Carrero, Ana Barcelo Mendiguchia, Andrea Calle Moscoso, Ignacio Garcia Recuero, Ana Romance Garcia, Alicia Muñoz Gallego

Hospital 12 De Octubre, Madrid, Spain

Speaker: Monica Gimeno Carrero

Introduction: Neurofibromatosis type 1 is a fairly frequent autosomal dominant phakomatoses disorder. It has a great clinical variability with multisystem involvement. Most neurofibromas are benign, but in the orbitofacial region (up to 22%) they have a huge growing potential that leads to devastating functional and cosmetic defects. Therefore subtotal anterior exenteration is most of the times necessary in patients with a buphthalmic and blind globe due to a massive orbital and eyelid plexiform neurofibroma.

Methods: We present a 10 years old boy with type 1 neurofibromatosis with recurrent orbitofacial plexiform neurofibromas from birth. The patient required five-step surgical interventions to resect the tumor and reconstruct the orbito-facial tissues.

Results: Repeat debulking procedures were necessary in the setting of tumour progression. In first surgery a full thickness wedge resection of the lateral third of the right upper eyelid was done. In the second surgery, a subtotal exenteration of the right eye with further debulking of the orbital, parotid and frontal regions was performed. The orbitopalpebral neurofibromas were resected on the third surgery and a medial transnasal wire mesh and a external canthopexy to raise both canthus were needed. In the fourth intervention, neurofibromas were resected by a team of neuro and maxillofacial surgeons by performing a frontotemporal craniotomy and opening the peri-orbit. In the last surgery, at 10 years of age, further debulking of the right upper eyelid and of the temporal, orbital and glabellar regions neurofibromas were performed.

Conclusion: The main objectives of oculoplastic management in these patients with orbitofacial Neurofibromatosis is to preserve the vision and to improve cosmesis. Orbital plexiform neurofibroma usually causes progressive disfiguring of the orbital, facial, and temporal areas. Most of the times, complete excision of neurofibroma is impossible, due to the extensive, diffuse soft-tissue infiltration and lack of encapsulation. Repeat debulking procedures are necessary to manage the tumour progression, which occurs at the margin of a previous resection. Many times preservation of a non-functional globe is not possible in severe Neurofibromatosis that causes significant deformity and they require radical resection that may include enucleation or exenteration.

P 54

The Luck of the Irish? A case of PKU, NF and ONG

Conor Malone, Christine Bourke, Chetty Shivona
Sligo University Hospital, Sligo, Ireland

Speaker: Conor Malone

Background and history: An 11-year-old girl presented to clinic with a 3-month history of gradual painless decrease in vision in the left eye; however, her parents felt she had recently developed a right-sided enophthalmos. The child had a history of phenylketonuria (PKU) which was well controlled, but otherwise was well, thriving socially and educationally. Her parents and brother had no complaints. There was no history of tick bites or exposure to other disease vectors.

Examination: On presentation, visual acuity was 6/6 in the right eye and 6/12 in the left eye. Gross examination was normal and there was no proptosis on exophthalmometry. Ocular motility and anterior segment examination were normal, with normal pupillary responses. On fundal examination, there was left-sided optic disc swelling. The right fundus was normal.

Diagnostics: Full blood count, renal function, Lyme titres, and auto-immune panels were all normal. Optic nerve head OCT showed left optic nerve swelling. CT brain and orbits was performed, which revealed a left retro-orbital mass involving the optic nerve, confirmed on MRI. A diagnosis of Dodge grade 1 optic pathway glioma was made. On physical examination, she had skin lesions on her scalp and abdomen which appeared to be café au lait macules, consistent with a diagnosis of neurofibromatosis. She was referred to the national paediatric oncology centre.

Conclusion: This girl with a background of PKU presented with a left optic nerve glioma secondary to neurofibromatosis. This is an unusual case of multiple co-pathologies with no family history of any chronic or hereditary conditions.



P 55

Resolution of Detachment of the Neuro-epithelium with Dexamethasone Intravitreal Implant in Refractory Juvenile Idiopathic Arthritis-Associated Uveitis

Ana Ortueta-Olartecoechea, Pilar Tejada-Palacios, Cristina López-López, Jaime de Inocencio-Arocena, Alicia Muñoz-Gallego, Ana Dorado-Rosado
Hospital Universitario 12 de Octubre, Madrid, Spain

Speaker: Ana Ortueta-Olartecoechea

Introduction: Therapy of uveitis in children represents a challenge for ophthalmologists. This condition can have an insidious onset that can lead to visual loss. The most common cause of pediatric uveitis is Juvenile Idiopathic Arthritis-associated uveitis (JIA-U). Intermediate, posterior or panuveitis anticipates a difficult control of the inflammatory response, which cannot rely on topical therapy alone. This scenario requires a multidisciplinary approach and treatment to improve the prognosis of the uveitis.

Methods: We present a case report of a patient diagnosed with JIA and chronic uveitis refractory to maximum topical and systemic treatment.

Results: A 6-year-old child was diagnosed with JIA at 2 years of age and he developed an anterior uveitis after 2 years that presented an unremitting course which waxed and waned over time. Topical treatment was ineffective and methotrexate was initiated early without significant response. Biological therapy was therefore associated without a significant improvement. Due to gastrointestinal intolerance methotrexate was substituted by azathioprine. After several months of treatment with azathioprine and golimumab, he presented anterior uveitis in both eyes with detachment of the neuro-epithelium in his right eye (OD), decreasing his visual acuity (VA) in his OD from 0.5 to 0.3 and remaining 1 in his left (OS) eye according to the decimal scale. Oral prednisone at 1 mg/kg/day was added to his regimen without any improvement of the macular inflammation. After 1 month a dexamethasone intravitreal implant was placed in the OD. One month after the injection, complete resolution of macular edema was observed being his VA of 0.5. Unfortunately, uveitis in his OS remained active despite topical and systemic treatment so it was decided to change from azathioprine to mycophenolate mofetil while maintaining golimumab.

Conclusion: Intermediate, posterior, or panuveitis are often difficult to treat and require systemic therapy. Multidisciplinary management is essential when using systemic corticosteroids, disease modifying anti-rheumatic drugs and/or biological therapy. We decided to use a dexamethasone intravitreal implant in our patient to control refractory macular inflammation with very good results and no complications. Although the use of these devices in children is limited and their safety and effectiveness have not been established yet we consider that they represent a good option in refractory macular inflammation.

P 56

Traumatic avulsion of the optic nerve: a case report

Gábor László Sándor¹, Béla Csákány¹, Zsuzsanna Récsán¹, Gábor Rudas², Zoltán Zsolt Nagy¹, Erika Maka¹

¹ Department of Ophthalmology, Semmelweis University, Budapest, Hungary

² MR Research Centre, Semmelweis University, Budapest, Hungary

Speaker: Gábor László Sándor

A 13-year-old girl was referred to the Department of Ophthalmology, Semmelweis University, because of a blunt eye trauma. According to the medical history obtained from the girl and her mother she was playing alone in an empty, giant parrot cage made from steel. The cage fell down suddenly and a part of the cage hit the girl's left eye. After the accident she checked her visual acuity and she recognised, there was no light perception on the left eye and she felt foreign body sensation. Slit-lamp examination showed a wound in the inferior bulbar conjunctiva. There was vitreous haemorrhage, therefore the fundus examination was limited, however diffuse retinal ischaemia was visible. Acute MRI, CT and ultrasound examination revealed intrabulbar haemorrhage, peri- and retrobulbar hematoma, thus the exact evaluation of the optical nerve was not possible. We gave local and systemic antibiotic and corticosteroid therapy. The vitreous and peribulbar haemorrhage absorbed within some days, but there was no light perception anymore. A cavity on the optic nerve head and peripapillary ischaemia and atrophy was visible biomicroscopically. A re-examination via MRI showed an optical nerve injury on the left side. Our purpose is to show this case of optic nerve avulsion, a rare presentation of ocular trauma.



Poster Abstracts

P 57

Juvenile Idiopathic Arthritis Associated Uveitis- When the Imaging Technology Helps the Treatment: A Case-report

Lilla Smeller, Nicolette Sohar, Rózsa Dégi, Edit Tóth-Molnár

Department of Ophthalmology, University of Szeged, Szeged, Hungary

Speaker: Smeller Lilla

Introduction: We report a case of a 13-year-old boy who was referred to the Department of Ophthalmology due to severe redness and pain in his left eye and unilateral uveitis.

Methods: Retrospective and descriptive case-report based on data from clinical records.

Results: A 13-year-old boy presented with decreased vision in his left eye for 2 weeks. He was diagnosed to have anterior uveitis and he was started on intravenous dexamethasone, but his ocular signs and symptoms became worse. When he arrived at the Department of Ophthalmology, on ophthalmic examination the best corrected visual acuity (BCVA) was 1.0 in the right eye and 0.6 in the left eye. Slit-lamp examination revealed unilateral cilio-conjunctival hyperemia, anterior chamber cell 3+ and flare 2+ and an anterior vitritis. Central macular oedema was observed on optical coherence tomography (OCT). JIA disease was suspected. Until we had the diagnosis, the BCVA worsened on the left eye. We decided to give local steroid. Oral methotrexate (MTX) (20 mg/week) was given. The central retinal thickness (CRT) and the BCVA did not get better, we had to repeat the injection. After three injection and starting the MTX therapy, symptoms improved steadily. OCT provides a faster and easier, non-invasive method for diagnosis and helps us to monitorise the activity of uveitis in children. OCT also helps us to give the optimal and most effective therapy.

Conclusion: We report a case of JIA patient where intravenous and oral steroid use was limited, but the inflammation signs improved on MTX and local triamcinolone injection. This case-report emphasizes the importance and effectiveness of prompt local steroids treatment in case of JIA patient following with the help of imaging techniques.

P 58

Sub-tenon triamcinolon acetone treatment in juvenile uveitis

Nicolette Sohár¹, Lilla Smeller¹, Viktoria Sümegi²

¹ Department of Ophthalmology, University of Szeged, Szeged, Hungary

² Department of Pediatrics, University of Szeged, Szeged, Hungary

Speaker: Nicolette Sohár

Introduction: Approximately 5% of the uveitis population are children, younger than 16 years. The special challenges in treatment of uveitis in children are a great concern today. They may be at special risk of complications because the inflammation is frequently chronic, and the diagnosis is often delayed because of no noticeable signs and symptoms, and failure to report changes in vision. The systemic treatment with corticosteroids for non-infectious uveitis in childhood has an impact on the immature immune system and the developing bones. When a more posterior effect is necessary periocular corticosteroids can be administered. We retrospectively studied the data of children with uveitis, treated with sub-tenon triamcinolon acetone at the Department of Ophthalmology of Szeged.

Methods: We treated 40 uveitic children at the Department of Ophthalmology between 2017 and 2018. They were 18 girls and 22 boys, 1-18 years of age. Their ophthalmological examinations included visual acuity, IOP, exams with slit lamp, OCT and funduscopy.

Results: We studied the data of 5 patients treated with sub-tenon triamcinolon acetone. All of the patients had intermediate and posterior uveitis, and they received three injections 3 weeks apart. Their vision improved after the prompt treatment and the cystoid macular oedema had resolved. To enhance their status of minimal uveitic symptoms, they were started on methotrexate therapy.

Conclusion: Juvenile uveitis can cause several complications, and can decrease visual acuity. Treating these children could be adventurous. The best route and dose is determined for each patient individually, but the minimum amount needed to control inflammation should be used to reduce complications. Sub-tenon approach works to deposit a long lasting steroid around the eye and the side effects are fewer than in systematic treatment.



P 59

Optical coherence tomography of the anterior segment in children and adolescents with ocular trauma

Beata Urban¹, Alina Bakunowicz-Łazarczyk¹, Monika Fedor²

¹ Medical University of Białystok, Białystok, Poland

² Białystok University Children's Hospital, Białystok, Poland

Speaker: Beata Urban

Introduction: Optical coherence tomography OCT Visante is the safe, non-contact method of imaging the anterior segment of the eye, which allows its biometric and morphologic evaluation. The aim of this study was to present the anterior segment of the eye using OCT Visante in children and adolescents after ocular trauma.

Methods: Optical coherence tomography OCT Visante (Carl Zeiss Meditec) was performed in 6 patients (5 boys and 1 girl), 10-16 years of age, hospitalized in Department of Pediatric Ophthalmology and Strabismus because of ocular trauma.

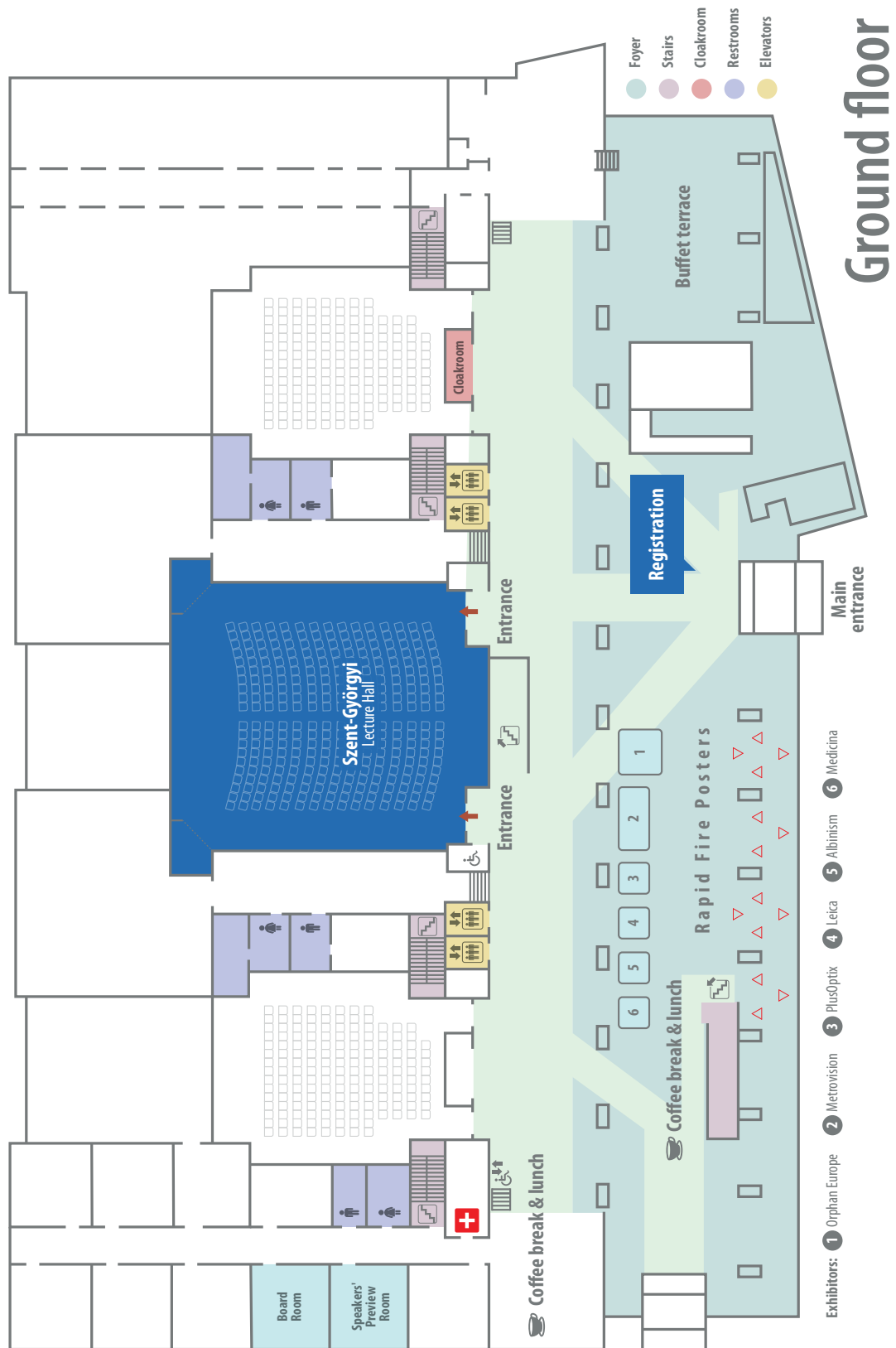Results: OCT Visante revealed changes in the anterior segment structures after ocular trauma (e.g. intumescent cataract), even when there is total loss of corneal transparency or hyphaema.

Conclusion: Optical coherence tomography Visante OCT provides easy visualization and high-resolution documentation. Its ability to image anterior segment structures despite the presence of an opaque cornea seems especially important. This technique can be very useful in children and adolescents with ocular trauma.





Exhibition Plan





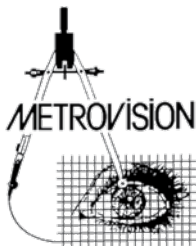


Sponsors

GOLD SPONSOR



SPONSORS & EXHIBITORS



Notes





Notes



Organizing Secretariat

TENSI LTD.

Komjádi Béla u. 1.


1023 Budapest, Hungary

Tel.: +36-1-345 1567

E-mail: congress@tensi.hu

Web: <https://tensi-congress.hu>





EPOS 2019 RIGA



30.05.-1.06.2019

From common
to rare diseases:
Advances in Paediatric
Ophthalmology

